

RADICAL TREATMENT OF THE ETHMOID:
INTRANASAL.*

BY RALPH A. FENTON, M. D.,†

PORTLAND, ORE.

Approach through the narrow threshold of the nostril should impose a certain caution upon the operator, and his indication for operation should be an ethmoiditis limited to accessible intranasal cells. Contraindications of a general nature include disease which may be implanted in or become localized in the operative field, such as tuberculosis and syphilis; disease affecting metabolism, such as diabetes or chronic nephritis, especially when associated with hypertension; severe anemia, especially with relative lymphocytosis; hemophilia, or any prolongation of bleeding or clotting time from nonhereditary causes, may all forbid or at least delay resort to radical intranasal surgery. Local contraindications include narrowed passageways, whether the small nostril of childhood, or the acquired atresia of healed septal abscess or other severe loss of substance in the vestibule and upper septum. Orbital or intracranial complications of ethmoid suppuration forbid intranasal work, except as a step in adequate external operations. If a coexistent suppurative process in the homolateral frontal or maxillary requires radical external operation, naturally the ethmoid may best be reached at the same time externally.

Allergic hyperplasias affecting the ethmoid are not in our experience suitable for radical surgery, unless secondary stasis of exudates has led to purulent invasion. Such cases repay conservative management.

*Read as part of Symposium on the Ethmoid, Before the American Academy of Ophthalmology and Otolaryngology, Atlantic City, October 21-25, 1929.

†From the Department of Otolaryngology, University of Oregon Medical School, Portland.

Freedom from external scarring and suturing is an obvious advantage, and no disturbance of the orbital contents, save occasional ecchymosis, is likely. Escape from the annoying psychic effect of transient diplopia, such as may readily occur in the external orbital route, is likewise a distinct advantage.

Most important is the fact that where time permits, intranasal surgery may be accomplished in several stages, permitting meanwhile careful study of the ethmoid. Limited areas of the ethmoid may thus be reached, leaving other parts relatively undisturbed. This conservative tendency is gaining acceptance within recent years, in contrast with the very radical intranasal surgery of ten years ago.

Accessibility of the agger nasi and of middle turbinate cells is obviously greater by the intranasal route. (Fig. 1.) The field of vision of the operator is, however, at first rather strictly limited to the anterior halves of the inferior and middle turbinates, the agger nasi and the nasal septum. Anything beyond,

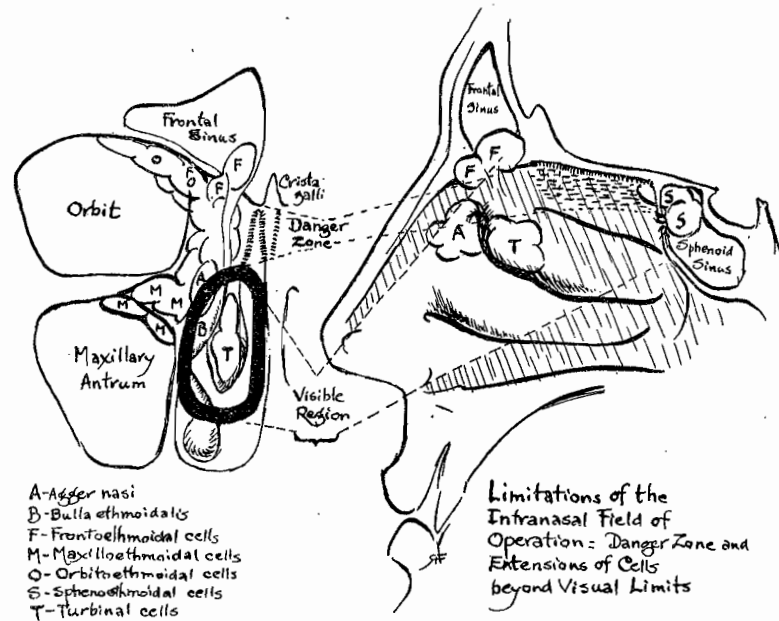


Fig. 1.

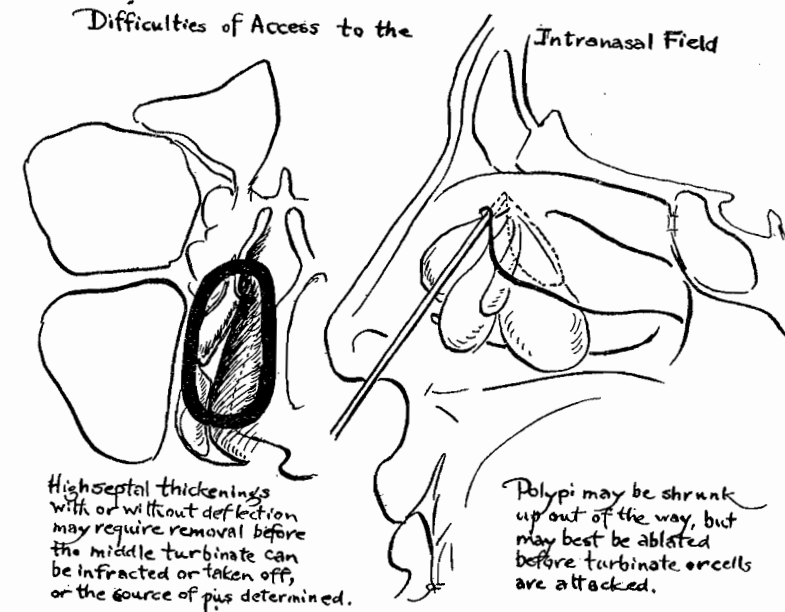


Fig. 2.

such as the bulla, hiatus and infundibulum, requires extensive shrinkage and often preliminary septal or turbinal work. Extranasal cells in the orbital roof, frontal bullae, between orbit and antrum, lateral to the sphenoid¹—are utterly inaccessible to intranasal procedures.

Danger of getting lost in the posterior ethmoid, if the head of the patient be turned up from the horizontal,² has been a very real peril in all procedures where the ends of instruments are out of sight of the operator. Very slight anomalies in this complex grouping of dural prolongations, olfactory and visual nerves and blood vessels may lead to complications varying from retrobulbar hemorrhage to optic neuritis or meningitis. Special training based upon dissection, cadaver work and operative experience under the eye of a competent teacher, are needed before intranasal ethmoid work should be essayed. Such is the opinion of Luc,³ Tilley,⁴ Hajek,⁵ Mosher,² Skillern,⁶ Sluder⁷ and many other distinguished clinicians.^{8 9 10 11 12 13 14} Competence may not be acquired in this field by reading or by study of drawings. Depth perception must be accurate, and

important landmarks must be recognized, in a field likely to be dark, narrow and bloody.

Appropriate preliminary resection must be done if access to the ethmoid is hindered by high septal thickening, with or without deviation. (Fig. 2.) Such resection must often precede the equally necessary and desirable infraction of the middle turbinate. Also occlusive masses of anterior polypi should be removed, as far up as possible, with traction of the snare on their pedicles. Choanal polypi are almost always from the maxillary antrum, but may interfere with access to posterior cells. The latter may, like the antrum, be full of edematous or hyperplastic mucosa but almost never originate pendent polyps. The bulbous-tipped middle turbinate, which contains a cell, must usually be resected.

An effort should be made, by studying stereoscopic radiographs, to determine whether extranasal extensions of the ethmoid are present. Ocular symptoms—transitory dimness of vision, flickering photophores, paracentral scotomata, reduction

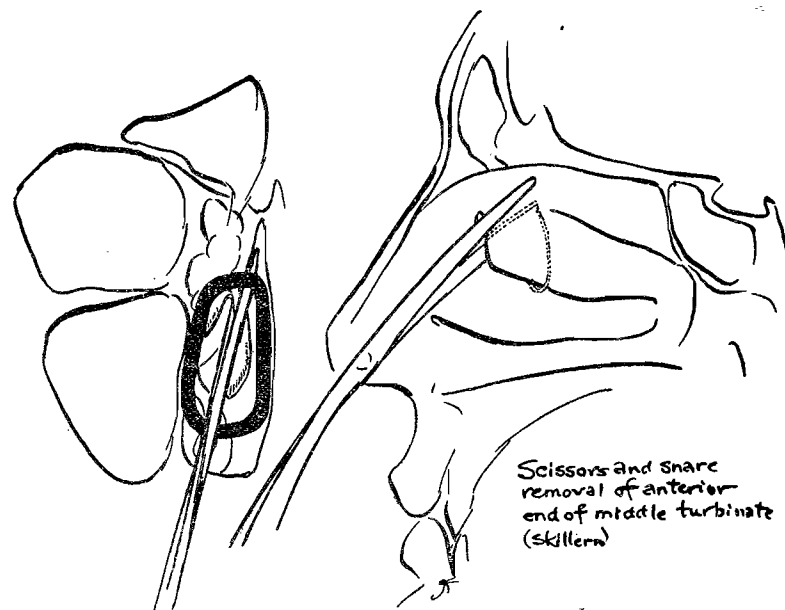


Fig. 3.

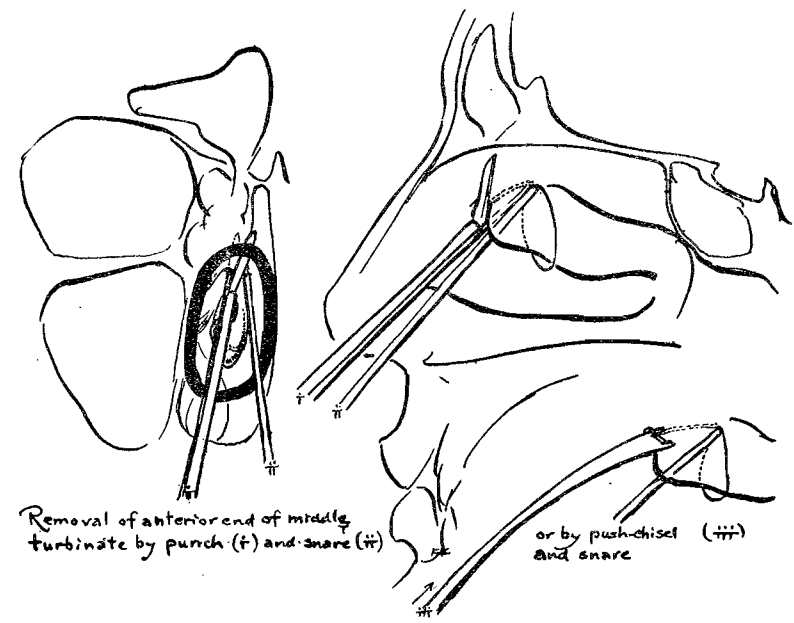


Fig. 4.

of red-green sensitiveness—suggest radiographs in the positions of Rhese or White, to show possible encroachment upon the optic nerve by a posterior ethmoid cell. Lipiodol after ephedrin, by the suction technic of Proetz, has not helped us in anterior cells, though it is very useful occasionally in the posterior cells, as in the sphenoid.

Location of discharge should be accurately decided before the type of operation is selected. The ostia cannot be seen; but (having ruled out frontal and maxillary involvement) long cotton tampons may be packed along under the shrunken middle turbinate, others in the superior meatus back to the sphenoid, and left in place from ten to forty minutes. Inspection will usually show secretion opposite the suspected cells, particularly if some dark silver-protein solution has been used on the cotton tampon for contrast.

The objects of intranasal radical operation, which may best be a succession of relatively conservative procedures, are three: First, to secure aeration, with consequent shrinkage and

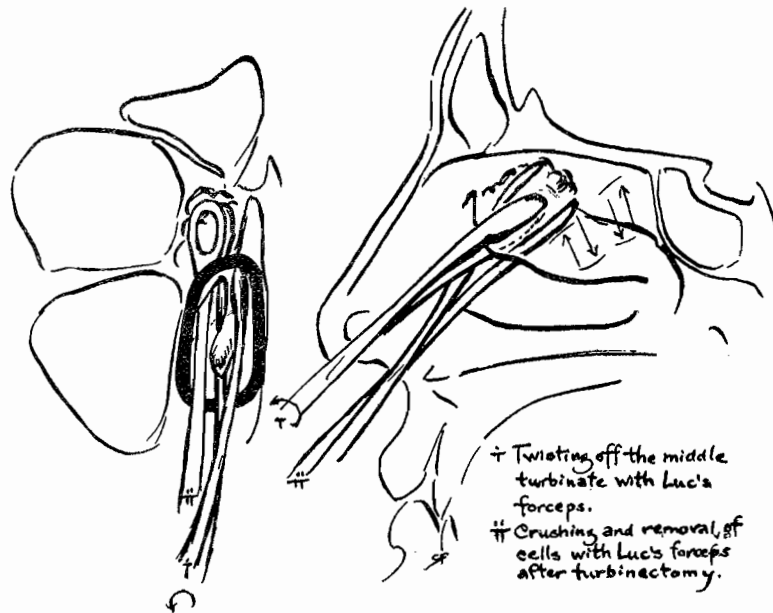


Fig. 5.

retraction of exposed hyperplastic mucosa; second, to secure drainage, where liquid exudates are actually present; and third, to avoid invasion of unaffected cellular structures during the operation if possible.⁶

Our own preference is for the scopolamin-morphin preparation, with local anesthesia. We prefer this to general anesthesia, which increases hemorrhage during operation and recovery, and subjects the patient to danger of pulmonary involvement from inhaled septic material and blood. Prior to entering the agger region, submucous injection of 1 per cent novocain with a very small amount of adrenalin may be made. For rapid surface action we use 10 per cent cocain with a little 1:1000 adrenalin, but where speed is no object we prefer 5 per cent butyn, also with adrenalin, and have had so far no ill effects from it. These are applied in the usual fashion with two small initial pledgets high up to block the sphenopalatine and anterior ethmoid region; then long cotton tampons, barely moistened by the solution, are placed under the middle tur-

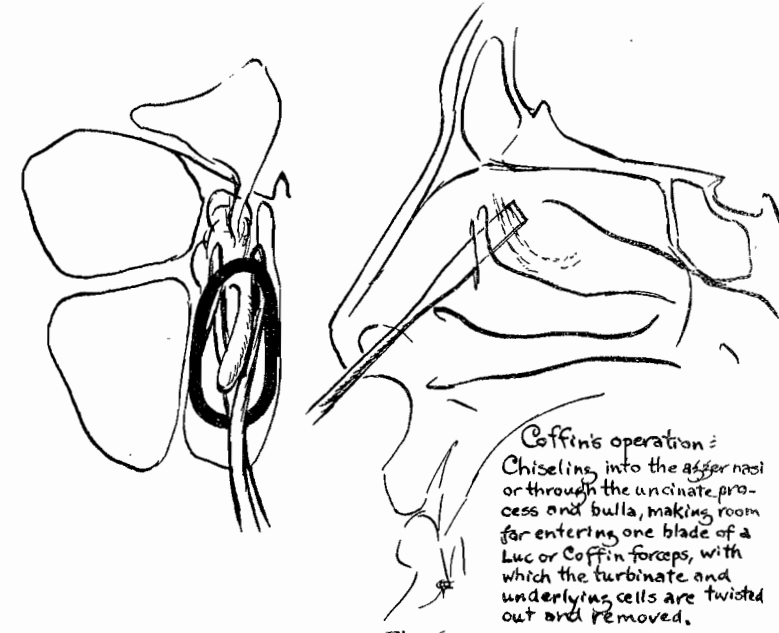


Fig. 6.

binate, about the bulla, and above the middle turbinate from the choanal rim forward about the superior turbinate. We do not like cocain "mud," although many excellent operators use it constantly. Above all, excess solution must not be allowed to run into the pharynx. We have found that the scopolamin-morphin preparation abolishes anxiety and its corollary of fainting or collapse, often ascribed to the local anesthetic. The bother of interruption for clearing the pharynx is avoided by packing a large cotton wad or rolled gauze strip into the choana before extensive procedures are started.

Intranasal ethmoid procedures, then, may be grouped as follows:

Improved methods of access—Septal resection, partial middle turbinectomy, infraction of the middle turbinate, removal of polyps;

Invasion of the anterior cells—Often associated with frontal involvement; operations on the agger nasi, uncinat and bulla (Coffin,¹⁵ Hajek,⁵ Halle,¹⁶ Skillern,⁸ Mosher²);

Invasion of the anterior cells carried back through the posterior cells without removal of the middle turbinate (Pratt¹⁷);

Invasion of the anterior cells carried back through the posterior cells with more or less complete turbinectomy (Mosher,² Tilley,⁴ Halle,¹⁶ Skillern,⁶ Coffin,¹⁵ Hajek¹⁹), or from behind forward (Moure-Portmann²⁰);

Bloc removal of the ethmoid mass with turbinate attached (Ballenger,²¹ Sluder⁷).

We have attempted to visualize simultaneously the picture presented to the operator as he looks up into the shrunk nose toward the middle meatus, with a lateral diagram of each operation. In this way we may see very quickly how much work has to be carried on beyond visual control, in many of these standard procedures.

We find the quick snip of scissors (Fig. 3) preferable to the crunch of forceps (Fig. 4) or the cracking of a push-chisel, for the initial cut of middle turbinectomy. A ratchet pattern pistol-grip snare with stylet, which may be reset, is

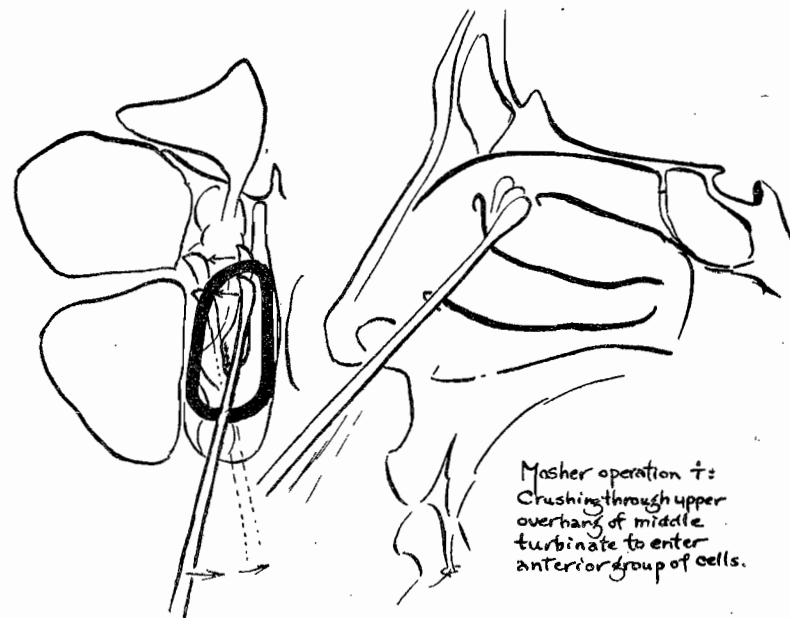


Fig. 7.

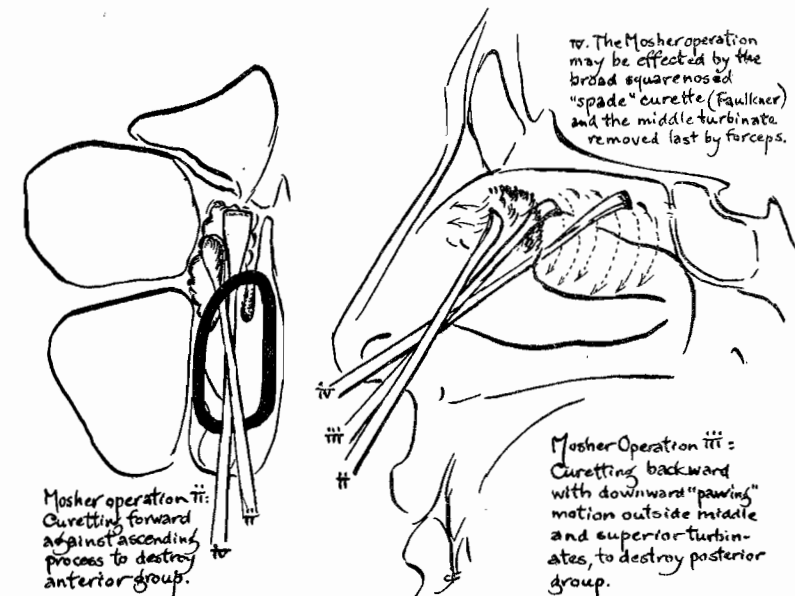


Fig. 8.

better than those which pull a long wire loop around a corner to get stuck in the canula. Twisting off the middle turbinate with Luc's forceps now seems unnecessarily brutal (Fig. 5), though excellent access is thus afforded to the bulla and other cells, which may be smashed up progressively in the broad and relatively safe jaws of these forceps.^{3 22}

Coffin^{15 28} enters the agger cell and transfixes the uncinata with a flat chisel (Fig. 6), thus making a path outside the bulla for one blade of his forceps. The other blade lies internal to the middle turbinate, and by a twisting closure the anterior mass is broken from place, giving access for such deeper removal as may prove necessary.

The Mosher^{2 4 9 10 22 26} operation smashes through the anterior overhang of the middle turbinate (Fig. 7) outward into the anterior group of cells, using his special curette. Thence, with a pawing motion backward and downward, he tears down the remaining septa and the posterior cells as far as the sphenoid, warning meanwhile against backward displacement of

the head. (Fig. 8.) The back part of the middle turbinate has and snare, except at the posterior extremity. Cells in front of the hiatus are curetted forward. The square-ended "spade" curette is safer in most hands than the original Mosher instrument.

Moure's^{12 20} operation reverses the Mosher technic (Fig. 9), using a curette almost as large as the Luc forceps, mounted in a double curved handle. The spoon of this curette is sharpened sidewise, but not on the rounded end. This formidable instrument is entered under the back end of the middle turbinate, swept up along the sphenoid wall and forward to the agger nasi, ripping out cellular structures from behind forward as the handle is depressed.

After removal of the anterior end of the middle turbinate, Hajek^{5 23} is accustomed to open the bulla with his ethmoid hook. (Fig. 10.) Grünwald's forceps are now used to bite away cells and tags and to open other anterior cells. This hook is also a useful instrument for raking down the superior

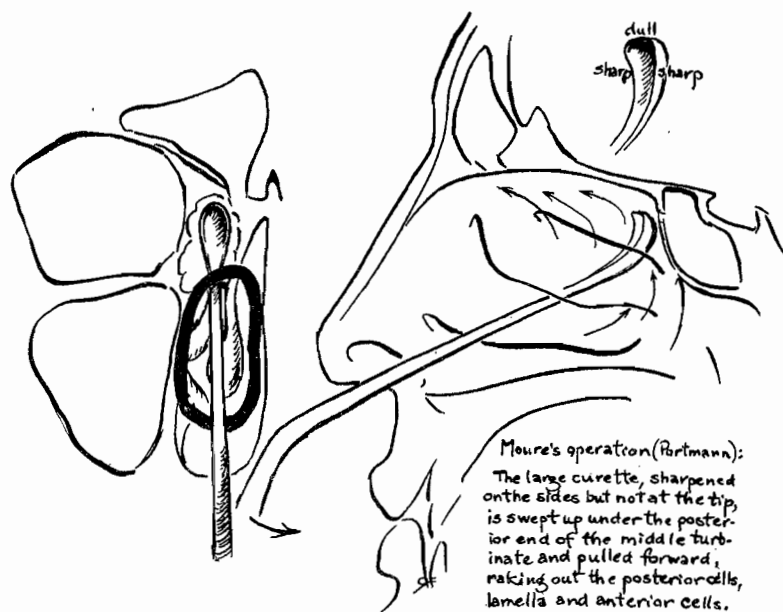


Fig. 9.

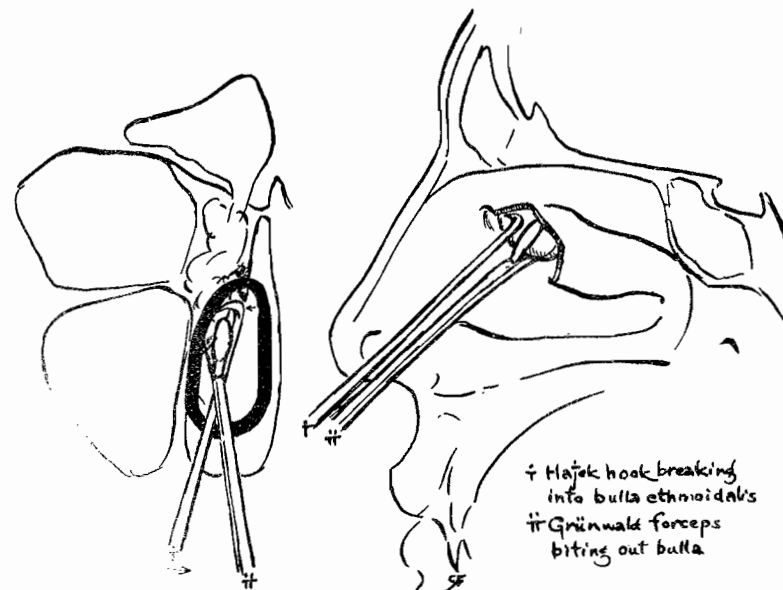


Fig. 10.

turbinate and posterior ethmoid group (Fig. 11) as far back as the sphenoid.^{18 19} Its beak should not be long enough to reach through to the orbital wall.

Halle's^{16 24 27} technic, primarily designed to give a broad entrance into the frontal (Fig. 12), by rolling down a mucoperiosteal flap from the region of the agger nasi and ascending process, gives excellent access also to the anterior ethmoid. Chiseling away the agger nasi and uncinata, Halle infracts the middle turbinate and bites away the ethmoid cells as far back as necessary under the intact turbinate. The flap is lastly turned back over the denuded agger region. Pratt¹⁷ does not remove the agger primarily but curettes forward to reach anterior cells. (Fig. 13.) He preserves the turbinate at all hazards, biting out cellular structures by touch "until solid bone is reached," and removing debris by special large ring curettes and cotton swabs.

The earliest bloc removal (Fig. 14), that of Ballenger,²¹ was effected by a large sickle-bladed knife which has a right or left

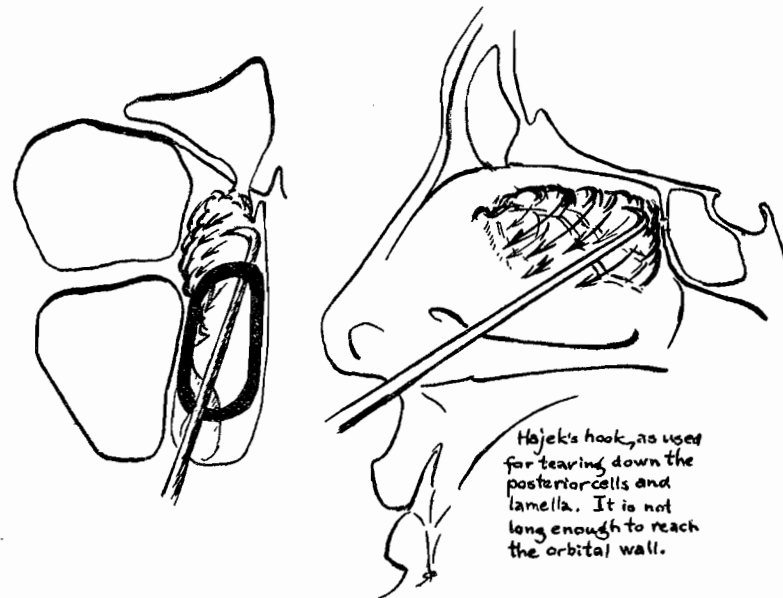


Fig. 11.

handed straight blade at its distal end, set at right angles and long enough to reach from the orbital wall almost to the septum. This powerful instrument is slipped up behind the bulla and under the middle turbinate, and as its handle is depressed the posterior cells, lamella and anterior cells are rocked loose. The entire ethmoid capsule with attached turbinates is thus sliced free and drops down for removal. Carelessness, or unperceived anatomic irregularities have brought about invasion of the dura, orbit or top of the septum during this operation.

Studer's^{7 20} operation required anterior severance under the middle turbinate (Fig. 15) by his short and powerful right-angle knife; he then slid the back of the same knife far along the cribriform plate and turned its square cutting tip outward, dragging it forward to connect with the previous suborbital cut. The turbinate and its underlying cells, freed if necessary by further lateral cuts through the cell walls, were removed by a snare placed as far back in the incision as possible. Par-

titions thus laid bare were smoothed by knife and forceps. As with Ballenger's operation, this bloc procedure has caused a good deal of trouble at the hands of unskilled operators.

What shall be the procedure of choice for the average operator? Men from various schools, trained by various teachers, will give various answers, of course. To invite discussion, and without any intention of dogmatism, we may suggest the following steps:

In hyperplastic cases:

- a. High septal resection. If speed is not essential, wait⁶ a while to see if room enough has not been gained;
- b. Removal of the anterior end of the middle turbinate; removal of polypi, as completely as possible. Again, wait,⁶ if time permits;
- c. Remove agger and uncinata by chisel;
- d. Break down a bulla with curette and forceps;
- e. Curette away affected anterior cells;
- f. Break into affected posterior cells with hook, smoothing up with forceps.

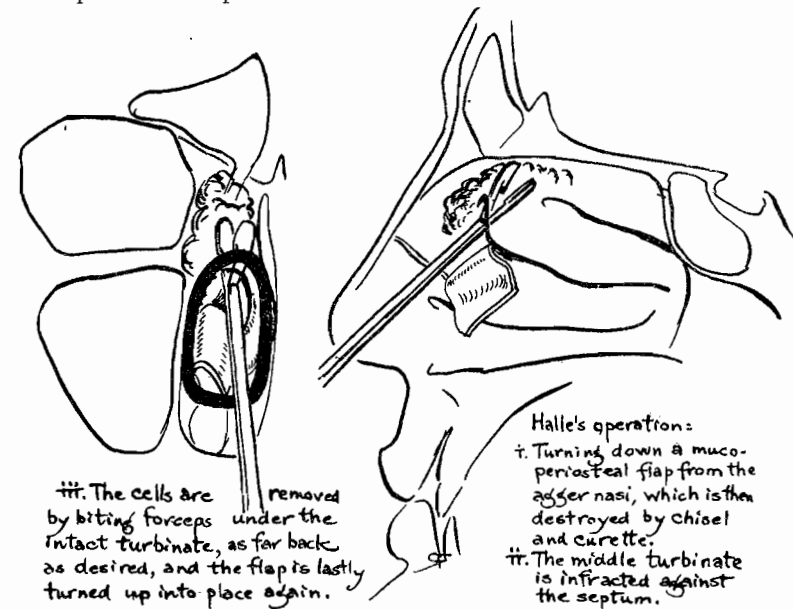


Fig. 12.

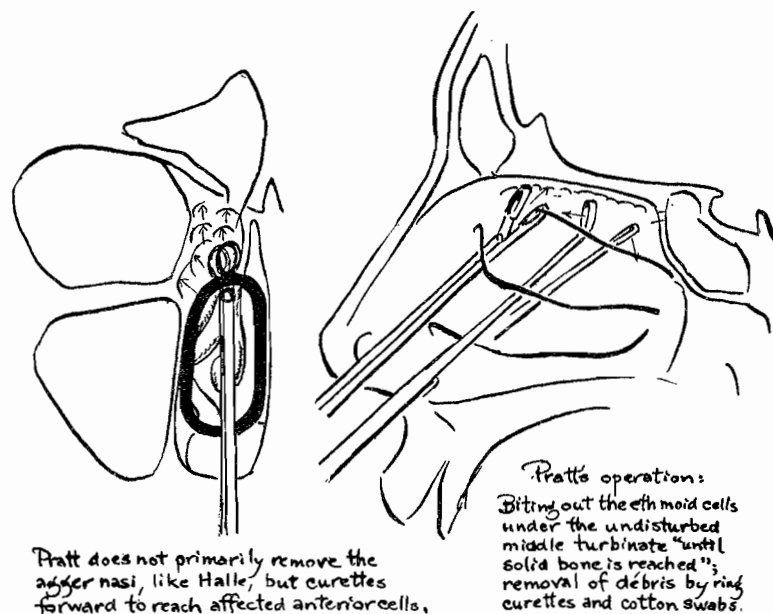


Fig. 13.

The last four steps may be carried out as one operation, but the piecemeal method of delaying the early steps will be found conservative of uninvolved areas and less likely to give rise to secondary infection therein—so-called recurrences—than the extensive one-stage operation.

General suppurative changes involving the entire ethmoid capsule, with or without polypoid degeneration, call for complete removal, and nothing is gained by delay.

In complete suppurative cases, therefore:

- a. High septal resection (if needed for access): The septum should be entered from the opposite side, if done simultaneously with the ethmoid;
- b. Middle turbinectomy with scissors and snare;
- c. Remove uncinata by chisel or destroy bulla by spade curette, depending on the anatomic conformation;
- d. Curette and punch away cells to anterior wall of sphenoid, working always back and down, never outward or upward.

Choice of instruments should be limited to those of rather broad rounded outlines (Fig. 16) to avoid inadvertent damage to vital structures. The danger zone at the upper outer angle of the posterior ethmoid must never be forgotten. Mosher's warning that the patient must keep his head level instead of tipping back (withdrawing from the operator) is of vital importance during all intranasal work; otherwise it is easy to lose sight of important landmarks, especially the posterior end of the middle turbinate. Slashing indiscriminately up into the olfactory nerve sheaths may cause fatal damage.

Immediate after-treatment of intranasal ethmoid operations should be limited to hemostasis—for oozing, light cotton tampons with thromboplastin, coagulen, etc., for a few minutes. The wound may be swabbed with 2 per cent mercurochrome, 3 per cent iodine, or compound tincture of benzoin. Packing should never be used.

Subsequent treatment should be of the slightest. Wound exudates should not be disturbed; clots and scabs are best left alone. There should be no swabbing, no spraying, no blowing

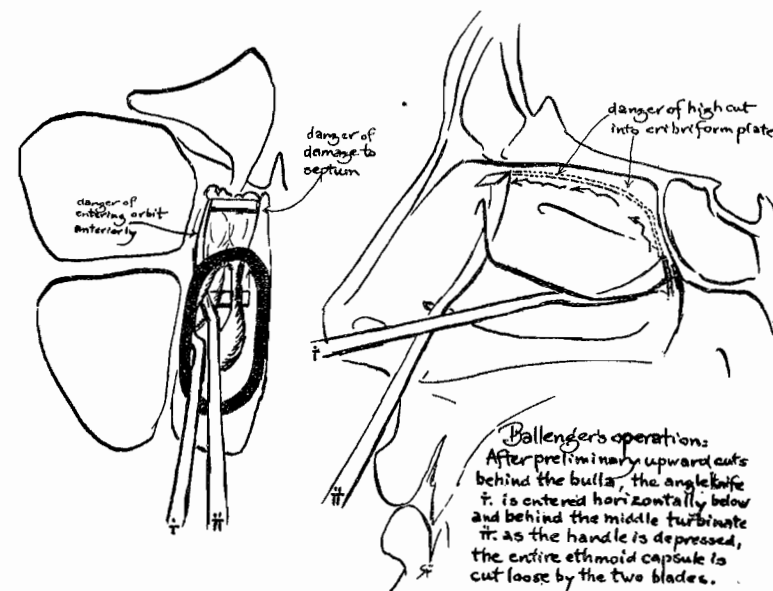


Fig. 14.

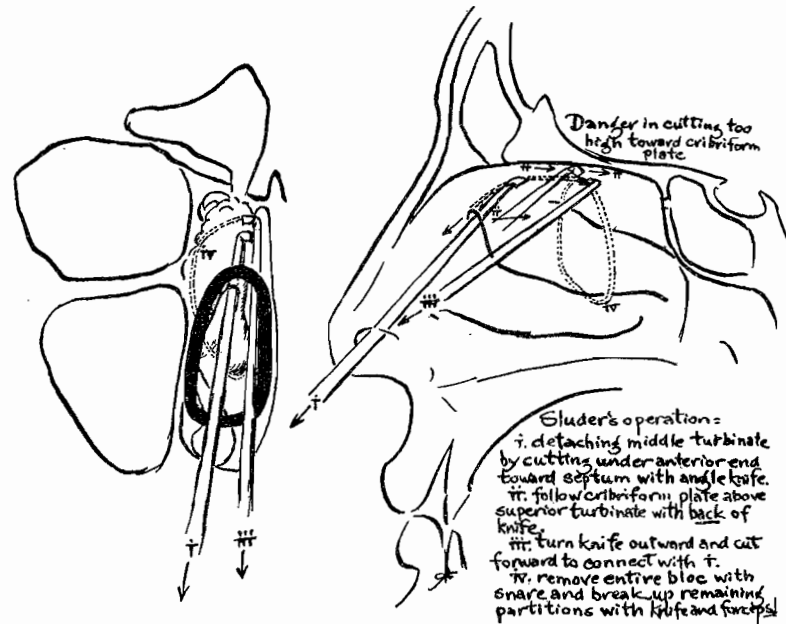


Fig. 15.

of the nose, and as little postnasal "hawking" as possible. A few drops of gomenol, $\frac{1}{2}$ per cent, in plain paraffin oil, or a small quantity of boric-lanolin (borofax) ointment, will allay local irritation and facilitate separation of crusts in a few days.

The normal process of healing should not be disturbed by fussy attempts to "clean up the wound." Annoying bleeding and secondary infection, with prolonged convalescence, may readily occur.

Within the strict limitations of its indications, intranasal surgery of the ethmoid has been found highly satisfactory; but excessively radical methods, carried out blindly through the narrow nasal pathway, have not stood the test of matured experience. No better conclusion can be made to this estimate of the present status of these procedures than these words of Herbert Tilley:³⁰ ". . . It must be stated emphatically that many of the local and general symptoms . . . may

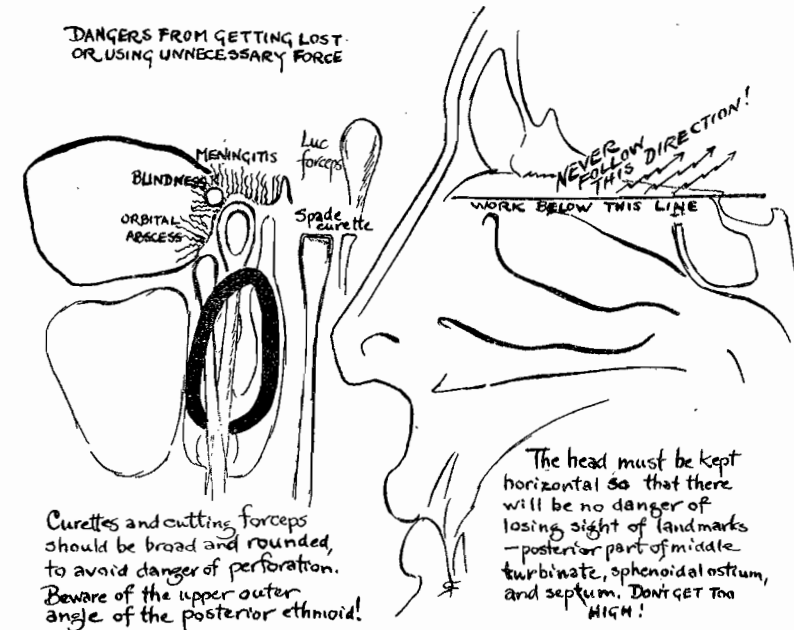


Fig. 16.

be practically cured by operations which involve little risk in skilled hands, even though the results may not survive the searching criticism of the surgical idealist. Hence it is incumbent on those who deal with these matters—(1) to make an accurate diagnosis of the extent of the lesion; (2) to determine how far the conditions probably threatens the health, happiness and even the life of the patient; and (3) if an operation be decided upon, to bring to it a greater combination of anatomic knowledge, caution and manipulative skill than is demanded in any other form of nasal surgery."

BIBLIOGRAPHY.

1. Neivert, H.: "Morphologic Variation as a Factor in the Symptomatology of Paranasal Sinus Disease." Arch. Otolaryn., 1:367, 1925.
2. Mosher, H. P.: "The Surgery of the Ethmoid Labyrinth." Tr. Sec. L., O. R., A. M. A., p. 241, 1914.
3. Luc, H.: "Les Suppurations de l'Oreille Moyenne, etc." 2nd ed., Paris, p. 353, 1910.

4. Tilley, H.: "Diseases of the Nose and Throat." 4th ed., London. p. 250, 1919.
5. Hajek, M.: "Nebenhöhlen der Nase." 5th ed. Vienna, p. 404, 1926.
6. Skillern, R. H.: "The Accessory Sinuses." 2nd ed. Phila., p. 349. 1916.
7. Sluder, G.: "A Surgical Consideration of the Upper Paranasal Cells." Tr. A. L. A., p. 200, 1916.
8. Mackenzie, Dan.: "Diseases of the Nose, Throat and Ear." London, p. 288, 1927.
9. Barnhill, J. F.: "The Nose, Throat and Ear." New York, p. 149, 1928.
10. Faulkner, E. R., in Jackson & Coates: "The Nose, Throat and Ear." Phila., p. 98, 1929.
11. Passow and Claus: "Operationen am Gehörorgan, an den Tonsillen und in der Nase." 2nd ed. Leipzig, p. 122, 1923.
12. Laurens, G.: "Chirurgie de l'Oreille, etc." Paris, p. 563, 1924.
13. Canuyt and Terracol: "Le Sinus Sphenoidal." Paris, p. 193, 1925.
14. Claoue and Vandenbossche: "Chirurgie des Maladies de l'Oreille." Paris, p. 153, 1919.
15. Coffin, L. A.: "The Surgical Management of Nasal Accessory Sinus Disease." Med. Record, 81:1021, 1912.
16. Halle, M.: "Die intranasalen Operationen bei eitrigem Erkrankungen der Nebenhöhlen der Nase." Arch. f. Lar., 29, 1:105, 1914.
17. Pratt, John A.: "The Present Status of the Intranasal Ethmoid Operation." Arch. Otolar., 1:42, 1925.
18. Skillern, R. H.: Loc. cit., p. 354.
19. Hajek, M.: Loc. cit., p. 467.
20. Portmann, G.: "Travaux Scientifiques." Bordeaux, p. 97, 1924.
21. Ballenger, W. L.: "Diseases of the Nose, Throat and Ear." New York, p. 233, 1909.
"The Exenteration of the Middle Turbinate Body and Ethmoid Cells en masse." Tr. Am. L., R. and O. Soc., p. 497, 1909.
22. Skillern, R. H.: Loc. cit., p. 352.
23. Passow and Claus: Loc. cit., p. 125.
24. Passow and Claus: Loc. cit., p. 126.
25. Thomson, St. Clair: "Diseases of the Nose and Throat." 3rd ed., New York, p. 292, 1927.
26. Thomson, St. Clair: Loc. cit., p. 312.
27. Hajek, M.: Loc. cit., p. 411.
28. Phillips, W. C.: "Diseases of the Ear, Nose and Throat." 7th ed., Phila., p. 647, 1928.
29. Tilley, H.: Loc. cit., p. 249.