

# PRINCIPLES OF THE OPERATION FOR CARCINOMA OF THE RECTUM

By ROBERT G. COFFEY, M.D., F.A.C.S., Portland, Oregon

*Reprint from*  
**SURGERY, GYNECOLOGY AND OBSTETRICS**  
*June, 1924, pages 723-738*

Published by Surgical Pub. Co., Chicago, U.S.A.



Fig. 24. *a*, The rectum has been excised and an exact watercolor picture made of the external surface of the gross specimen unopened. *b*, The rectum has been laid open and an exact watercolor drawing made of the cancer. This is a typical growth and is the most frequent location of cancer of the rectum in the curable stage.

*Principles of the Operation for Carcinoma of the Rectum.—Robert C. Coffey.*

## PRINCIPLES OF THE OPERATION FOR CARCINOMA OF THE RECTUM<sup>1</sup>

By ROBERT C. COFFEY, M.D., F.A.C.S., PORTLAND, OREGON

COMPLETENESS is the most important desideratum connected with a surgical operation for cancer. Considered biologically, from the standpoint of the mere eradication of the cancer itself, completeness is the ideal to be sought. Considered broadly in the interest of the patient, this ideal must sometimes be modified. For instance, the Wertheim operation for cancer of the uterus is ideal from the standpoint of removing the cancer, but it is the opinion of a great many very competent surgeons that the increased mortality following this radical or ideal procedure more than outweighs the increased number of permanent cures. In other words, it is the opinion of most surgeons that a modified operation is advisable as a general rule, in that the modified operation in a thousand given cases of carcinoma of the uterus will probably add a greater total of comfortable days of life than would be observed in a thousand patients treated by the more ideal method of Wertheim. The complete block dissection for cancer of the neck, including the removal of all the vital tissues, such as the carotid artery, jugular vein, and even the pneumogastric nerve, is ideal from the standpoint of removal of the cancer but we are always called upon to decide whether it is ideal from the standpoint of the patient. The same is true of cancer of the lower jaw or base of the tongue, for which a surgeon, by a

series of daring surgical maneuvers, removes these organs.

Some surgeons in operating for cancer of the uterus use the cautery and attack the most inoperable cancers, well knowing that more than likely both the rectum and bladder will be opened in the procedure if the operation is to be thorough. They seemingly disregard the other organs on the ground—I once heard a surgeon say: "We are dealing with cancer." We must remember also that we are dealing with a patient—a human being.

Cancer of the rectum has in the past been placed in this same category of borderline operability. The old Kraske one-stage operation, giving a mortality of 25 per cent or more with no control and no means of taking care of the fecal contents, was a most formidable affair. Who would want to be operated upon under such circumstances? Quite a few doubt, but many of those choosing the operation would doubtless be quietly hoping for more of fatalities. It is this most terrible and mutilating of operations that has caused surgeons from time to time to try more conservative procedures by which the sphincter muscle could be preserved. Unfortunately the growth returns, the patient has very poor control at best; and nearly all surgeons have abandoned the effort to preserve the sphinc

<sup>1</sup>Read before the Southern Surgical Association, December 11, 1923.

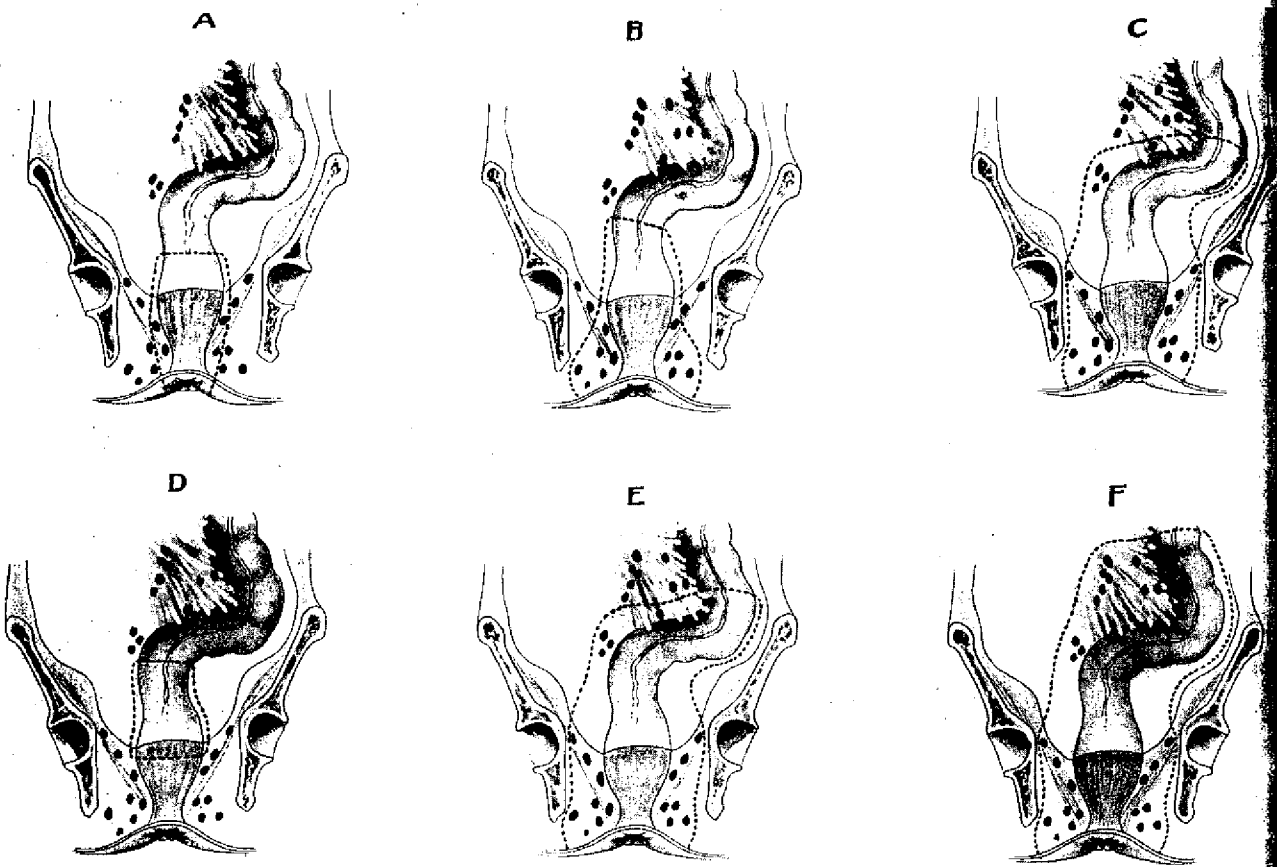


Fig. 1. *a*, Diagram showing the restricted nature of Kraske's operation. The rectum is merely dissected out as a tube containing a cancer, and the vulnerable tissues of the upward, lateral, and downward zones of spread are left. (Miles.)

*b*, Diagram showing the first step in the evolution of the radical operation. The peri-anal skin and the ischio-rectal fat were widely removed as these tissues have been found vulnerable to recurrence. (Miles.)

*c*, Diagram showing the extension of the operative field as a further step in the evolution of the radical operation. In addition to the peri-anal skin and the ischio-rectal fat, all of the levatores ani muscles and the lower part of the pelvic mesocolon were included as these tissues were found to be highly vulnerable. (Miles.)

*d*, Diagram showing the limited character of the removal in perineal resection and vaginal resection. (Miles.)

*e*, Diagram showing how much of the vulnerable tissue of the three zones of spread is left behind by the abdominal-anal operation. Even when the proximal end of the colon is brought down to the anus, the vulnerable tissues of the lower zone are left. (Miles.)

*f*, Diagram showing the final stage in the evolution of the radical operation. Whereas the vulnerable tissues in the lateral and downward zones of spread may be removed completely by an operation carried out from the perineum alone, the greater part of these contained in the upper zone remain out of reach. These tissues, which correspond to the axilla in the breast operation, can be removed only by the radical abdominoperineal method. (Miles.)

apparatus at the lower end of the rectum; for with a properly made colostomy in which the intestine is brought out through the left rectus muscle, the patient is by no means uncomfortable. Some such apparatus as the Delatour bag effectually serves as a reservoir to store the bowel contents. With this point settled, we are free to do a complete operation for cancer of the rectum. By completeness, we mean complete devascularization and removal of the involved and contiguous area. By devascularization, we mean the cutting

off of both the blood supply and the lymphatic and venous return circulation.

Contrary to the established belief, there are few parts of the body so favorably situated as the rectum for complete devascularization and removal of all the involved tissues in case of cancerous invasion. Most of the blood supply for the ampulla of the rectum and the recto-sigmoid, as well as that of the connective tissue and fat found in the hollow of the sacrum, comes through one vessel—the superior hæmorrhoidal artery. Most of the return

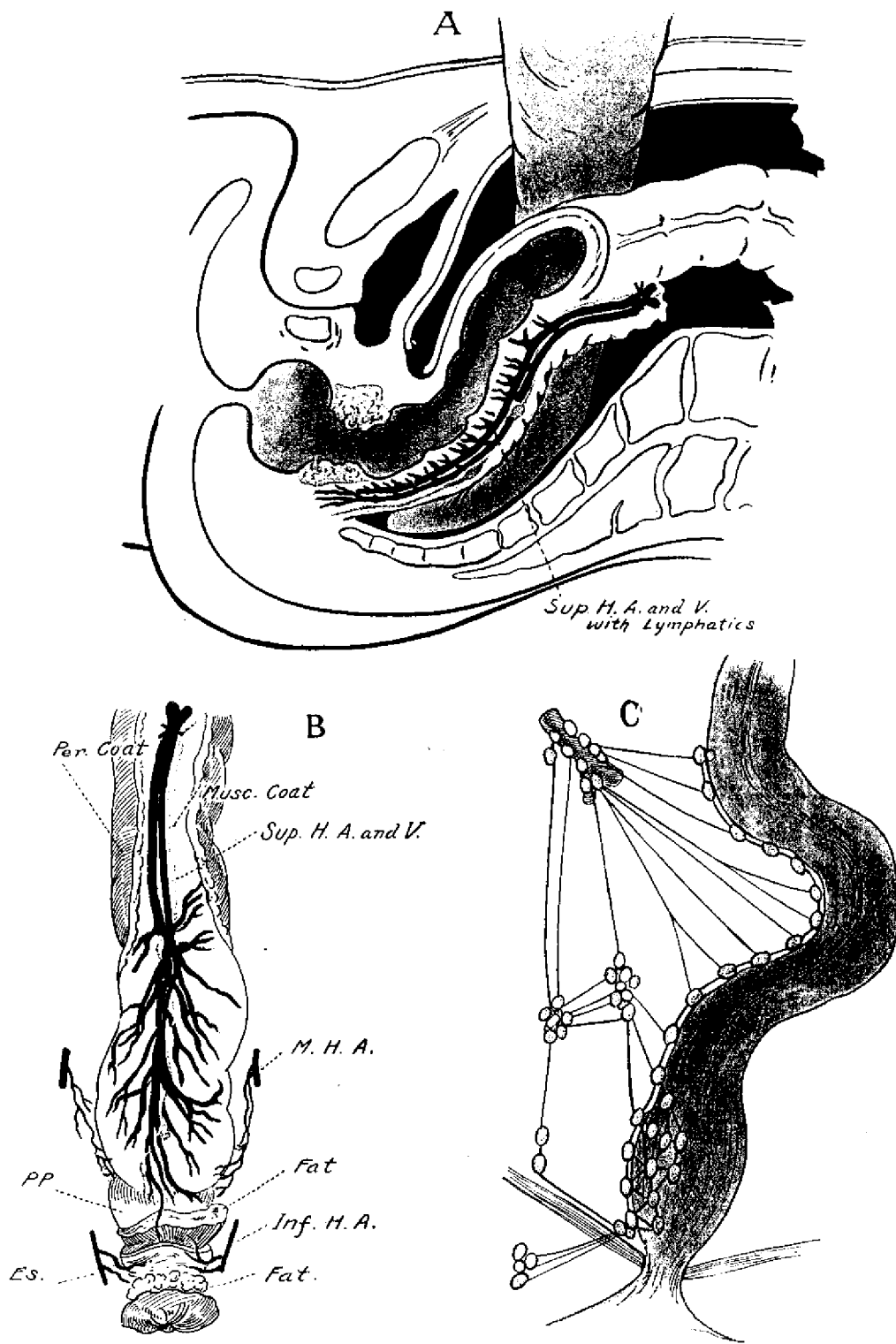


Fig. 2. *a*, Complete devascularization from above is possible by ligation of the superior hæmorrhoidal vessels at the promontory of the sacrum. Note arteries, veins and lymphatics. *b*, Direct view of superior hæmorrhoidal vessels and lymphatics which occupy the retrorectal space. The ligation of these vessels devascularize the ampulla of the rectum and rectosigmoid. *c*, Elaboration of Miles' picture showing the lymphatics of the rectum.

*Principles of the Operation for Carcinoma of the Rectum.*—Robert C. Coffey.

circulation goes back through corresponding veins and these vessels are accompanied by the lymphatics, which together serve as almost the sole avenue for the spread of the disease upward. These vessels may all be included in a single ligature placed opposite or just below their crossing of the promontory of the sacrum in the mesosigmoid. It will be seen by the composite colored plate (Fig. 2) that this ligature at once severs the blood supply and the venous and lymphatic return circulation, thereby removing the danger of hæmorrhage as well as upward metastasis during the further progress of the operation.

The article of Mr. W. E. Miles, which appeared in the *British Medical Journal*<sup>1</sup>, and was abstracted in the *INTERNATIONAL ABSTRACT OF SURGERY*<sup>2</sup>, gives a very lucid description of the lymphatic circulation and also a very clear description of the method of the spread of cancer of the rectum as follows:

"Operation undertaken for cure of cancer must be based on the pathological findings and the field of operation must embrace all tissues apt to become invaded. The question of operation therefore necessitates a knowledge of the method in which cancer of the rectum spreads and the paths it takes. The early stage of adenocarcinoma of the rectum is confined to the mucous membrane and submucous tissue. It is sessile and readily movable upon the subjacent muscular coat, gradually increases in size and spreads in three distinct ways:

"1. By direct extension through continuity of tissue.

"2. Through the venous system.

"3. By means of the lymphatic system.

"*Spread of growth by direct extension through continuity of tissue.* Although the tumor is freely movable at first, it soon becomes adherent. Extension takes place in all directions, but more in the transverse than in the longitudinal axis of the bowel. Adherence begins at the center or the oldest part of the tumor, but surface extension may progress more rapidly in one direction than another, thus fixing the indurated portion nearer one lateral margin than the other. It is difficult

to determine how long a growth has been the present. From observations of tumors in ampulla of the rectum, however, it may be inferred that by the time three-quarters of the circumference of the bowel is involved the growth is more than 1 year old. While the growth is extending around the circumference of the bowel, infiltration of the muscular coat is taking place. This penetration continues until it is arrested for a time by the lymph sinus between the outer surface of the bowel and the surrounding fatty tissue. The growth finally extends across this space and involves the perirectal fatty tissue and the fascia propria of the rectum. Penetrated fixation to the sacrum, prostate, bladder, uterus, or vagina is impossible until the fascia propria has been involved. This would not occur, therefore, until a year after the earliest symptoms indicating the presence of the growth. Direct extension of carcinoma of the rectum is comparatively slow, and invasion of the surrounding tissues does not take place until the greater part of the circumference of the bowel has become involved.

"*Spread of growth by the venous system.* Microscopic specimens afford evidence of direct invasion of venous radicals. It is, therefore, easy to understand how even in an early stage cancer cells may be detached and carried to a great distance from the primary growth, especially to the liver. Fortunately, this mode of spread is rare, and definite liver metastases are generally a late manifestation.

"*Spread of growth by the lymphatic system.* The most important route by which cancer cells are disseminated is through the lymphatic channels. In the rectum there are two distinct sets of lymphatic channels by means of which such spread takes place: i.e. the intramural and the extramural lymphatic systems. Dissemination in the intramural system is of very limited extent. The general scheme of the extramural lymphatic channels is represented in Figure 2, c. The various tissues traversed by these vessels are vulnerable to metastatic deposits. Corresponding to the three lymphatic areas there are three zones of spread: (1) the zone of downward spread which includes the peri-anal skin, the ischio-rectal fat, and the external sphincter muscle

<sup>1</sup> 1920, ii, page 730.

<sup>2</sup> 1921, xxxii, 280.

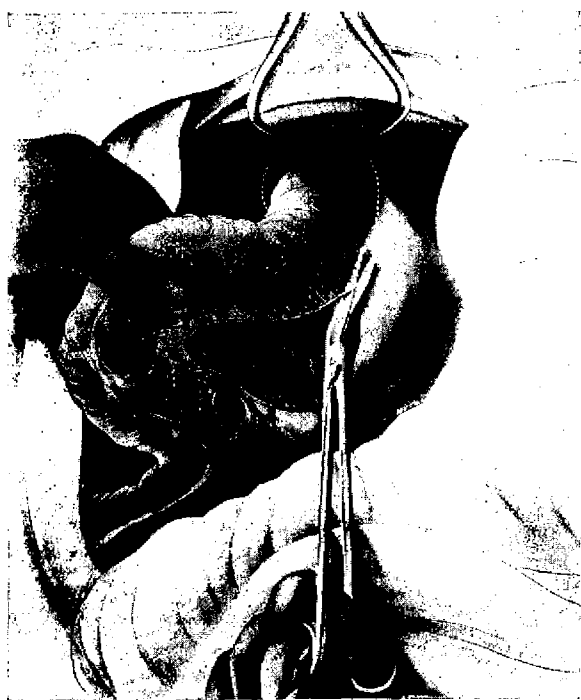

Fig. 3. The sigmoid is mobilized by cutting the peritoneum on each side of its mesentery. Dotted line indicates incision of peritoneum of cul-de-sac around rectum and between bladder and rectum with long handle angle scissors.

(2) the zone of lateral spread, which embraces the levatores ani muscles, the retrorectal lymph glands, the internal iliac glands, the base of the bladder, and the vesiculæ seminales, and, in the female, the posterior wall of the vagina, the cervix uteri, and the base of the broad ligament with Poirier's gland; and (3) the zone of upward spread, which includes the pelvic peritoneum, the pelvic mesocolon in its entirety, the paracolic lymph glands, and the group of lymph glands at the bifurcation of the left common iliac artery."

The author concludes that early growth in cancer of the rectum may metastasize widely into these zones and cannot be detected by ordinary rectal examination. He says: "The peritoneum, especially that portion which lies on either side of the parietal attachment of the pelvic mesocolon, is very often the seat of growth. Deposits, no doubt, begin in the subperitoneal lymphatic plexus, and the small intestine coming into contact with an exposed placque, may become infected and cause widespread dissemination. The pelvic meso-

colon is also very frequently the seat of metastatic deposits even in early cases. Lastly, the paracolic glands may become the seat of metastasis. Cancer cells do not spread according to the anatomical lymphatic distribution but according to laws of their own. Thus metastasis may occur in any or all of these zones irrespective of the position of the primary growth.

"Cancer of the rectum, regardless of its position, is apt to spread to the tissues of the three zones described. The most vulnerable of these are the ischioanal fat, the levatores ani muscles, the retrorectal glands, and the pelvic mesocolon. Therefore, these tissues must be freely removed in an operation for cancer of the rectum."

Figure 1 was taken from Miles' article and has been redrawn for the purpose of making more graphic the important lines. These figures show the relative thoroughness of the various operations which have been done in the past and Figure 1, f, represents the ideals of thoroughness to be sought after. This plate with Figure 2, which represents a composite picture of the important vessels to be noted in the operation for cancer of the rectum, together with the succeed-

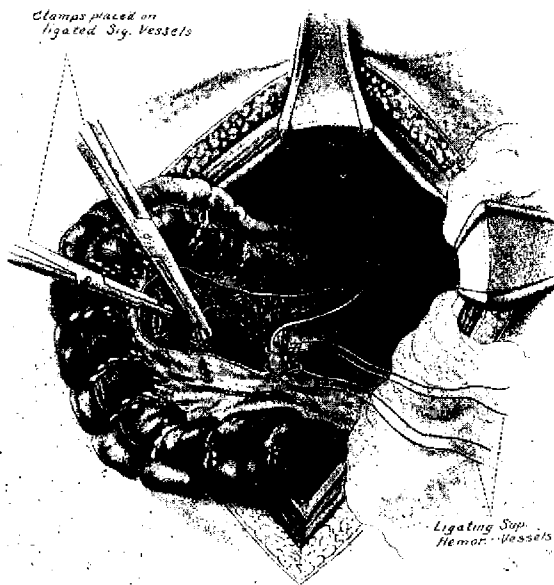


Fig. 4. Two ligatures placed around the superior hemorrhoidal vessels about 1 inch apart. The sigmoid arteries tied on one side and clamped on the other.

ing pic  
reader &  
operatic

Up to  
that in  
an arti  
comfort  
ing of  
Kraske  
lations  
of its v  
possible  
comple  
other c  
underg  
dous st  
as will  
taken  
for pe  
opened  
must b  
entery  
in the  
rectal  
ani m  
tissue  
the bl  
male.  
this of

Fig.  
the sev  
and bet  
are lift  
the coc

ing pictures in this article, will give the reader a graphic view of the enormity of the operation for removal of cancer of the rectum.

Up to this point, we are prepared to say that in the first place, it is possible to provide an artificial anus that permits a relatively comfortable continuation of life, thus disposing of one of the drawbacks of the original Kraske operation. Second, its anatomical relations to other organs, and the arrangement of its vascular and lymphatic supply makes it possible to remove a cancer of the rectum more completely and radically than almost any other cancer connected with the body. To undergo this radical operation is a tremendous strain on the vitality of the patient, for, as will be seen by these first two illustrations taken with those describing the technique for performing it, the abdomen must be opened and explored, the lower pelvic colon must be removed with all the fat of its mesentery and the fat found back of the rectum in the hollow of the sacrum and in the ischio-rectal space, all the levator and sphincter ani muscles and in front all the connective tissue up to the vagina in the female, and the bladder, prostate, and urethra in the male. There is much sewing to be done in this operation which requires a great deal of

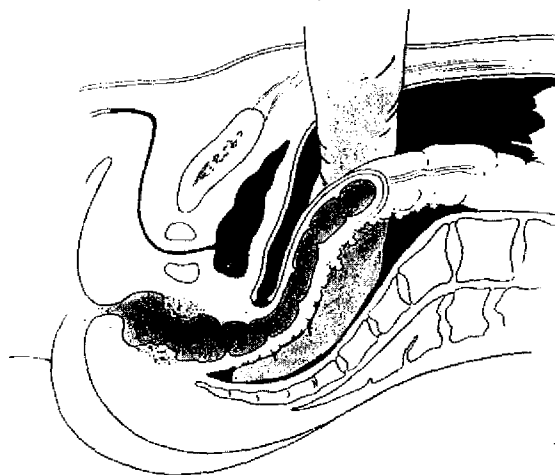


Fig. 6. Sectional view of Fig. 5.

time. In short, the radical operation for cancer of the rectum is one of the largest in surgery.

While it is true that some prefer the one-stage operation, I am very sure that the average operator, equally skilled in doing both the one-stage and two-stage operation, will obtain better results with the two-stage. While some individual patients have reparative material sufficient to make repair and at the same time keep up defense against infection throughout all the area involved in this operation, a large percentage of patients cannot put up the necessary defense all at one time. In attempting to do several operations in different parts of the body at the same operative session, I have frequently noticed a break-down of the defensive even to a point at which a clean abdominal incision would fail to unite. Therefore, it seems conservative and wise in very large operations to give nature all of her defensive forces with which to produce an unbroken physiological mechanism before the entire burden of repair is thrown upon her. And after the principal avenues of extension have been severed or devitalized, we can then safely give the natural forces time to make the necessary repair for a complete and physiological mechanism before the final stage of the operation is to be done. In the early part of my work I attempted to do the second operation too soon, say within 4 or 5 days after the first,

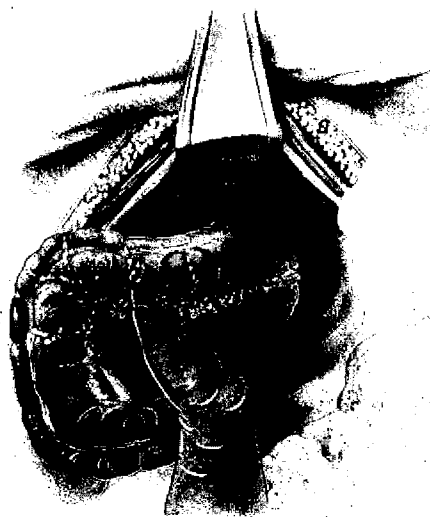

Fig. 5. The fingers of the left hand, insinuated between the severed ends of the superior hemorrhoidal vessels and between the cut peritoneal edges of the mesosigmoid, are lifting the fat from the hollow of the sacrum down to the coccyx.





Fig. 7. Clamping and cutting the sigmoid after the vessels have been ligated. Note that one of the clamps passes through the stab wound in the rectus muscle.

and was often disappointed by the breaking down of an uninfected abdominal incision or the giving way of the peritoneal surfaces as sutured. I therefore venture the dogmatic assumption that in order to get the best results, it is necessary to do this operation in two stages, for I contend that the extent of the operative procedures cannot be greatly abridged if we are to obtain the best permanent results. It is further interesting to note that no more radical operation can possibly be done if we are to have proper regard for the interest of our patient, for in line with the statement at the beginning of the article, any growth which involves other vital organs in the pelvis, such as the bladder, ureters, or the sacrum, should be considered inoperable when taken from the standpoint of the patient and should be treated by palliative measures.

Up to this point, I think we may reasonably assume first, that we can comfortably dispense with the organ involved. Second, the involved organ is so situated, constructed, supplied, and drained that it may be removed without seriously involving other organs. Third, it can more safely be thus



Fig. 8. Proximal sigmoid has been fastened to layers of abdominal wall and its end held closed with a clamp. Tube is passed up to end of distal sigmoid, where it is fastened by a strong double suture passed through the intestine and eyes of tube and tied. By pulling on the tube, the sigmoid is inverted and drawn out through the anus.

radically removed by utilizing the two-stage principle.

We are now confronted with the question: What two-stage method will assure a complete operation with the least drain on the vital forces of the patient with a resultant minimum mortality? It is not the purpose of this paper to discuss the relative value of the work of the great men who have led the way and shown us the possibilities in this field of surgery except in so far as it immediately concerns the principles under discussion. Suffice it to say that in all my early work I faithfully attempted to follow the work of Drs. W. J. and C. H. Mayo, whose work constituted largely a co-ordination and clinicalization of the best methods of European and American surgeons with their own original work and I think it will be generally conceded that certainly no better work has been done than that at Rochester. It was only about 10 years ago that I began to change

Opening the  
is placed to  
rectum

Fig. 1  
left  
a con  
the  
port

my  
use  
oth  
Mil  
var  
no  
ou  
vol  
the

the  
far  
was  
the  
pro  
sim  
lat  
the  
op  
by  
su  
de  
thi



Fig. 9. After the space between the sigmoid and the left lateral parietal peritoneum has been closed by suture, a continuous catgut is run along the mesosigmoid covering the raw fat edges with peritoneum down to the narrow portion of the cul-de-sac, where drain is inserted.

my methods from the established methods used there. In the meantime, a number of other men, such as Lockhart-Mummery, Miles, Jones of Boston, and others were also varying the established technique. I shall not discuss the relative merits of these various procedures but rather the principles involved in the whole subject as indicated in the title.

As has been said, the lowest mortality with the old one-stage Kraske operation was, as far as I know, achieved by the Mayos and was about 25 per cent. The first great drop in the mortality rate was when the two-stage principle was adopted. In this operation a simple colostomy was made. A few days later the last segment of the sacrum with the coccyx was removed and the radical operation performed. I did most of my work by this method for several years but I am sure it is not possible, certainly not for me, to do anything like as complete operation by this method as by the one we are now using.




Fig. 10. The suture line continues to bring the parietal peritoneum from the sides of the narrow pelvis around the drain until the abdominal incision is reached, making the drain extraperitoneal.

Furthermore, as far as I know when this method was in vogue, no one was able to bring the operative mortality below 12 or 15 per cent. I appreciate that the operative mortality would vary to a great extent according to the completeness of the operation, but I think the degree of completeness can be definitely standardized as to the amount of tissue removed and also as to operability and inoperability by the very definite lines we have already suggested in the paper, and which Miles has so accurately diagrammed.

The first question the operator has to decide is. What part of the operation is to be done at the first stage and what at the second? My belief is that the best results are obtained when the following principles are adopted for the first stage:

1. A completed physiological abdominal mechanism must be provided which is not to be disturbed afterward.
2. Complete devascularization of the involved and adjacent tissues from above. At the same time the devitalized structures must be mobilized and pushed down within easy reach of a sacral or perineal incision.
3. Separation of the retained physiological area from the discarded area by a quarantine pack which also serves the purpose of draining

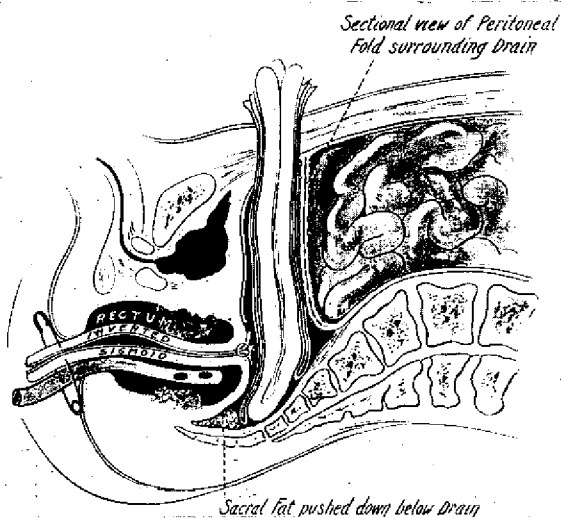


Fig. 11. Sectional view of drains which have been tubularized by the peritoneum of the pelvic wall. Fat in hollow of sacrum is pushed down, a drainage tube in rectum and inverted sigmoid held down by a safety pin.

away the débris of any sloughing tissue resulting from devascularization.

The first two principles were adopted in 1914 and published in the *Annals of Surgery*, April, 1915. The complete devascularization was followed by a sloughing of the devascularized tissue which first developed a large abscess and later broke into the rectum. While the patients lived through this septic period, it was anything but an ideal condition and a means for draining away the débris of the sloughing tissue became imperative if these principles were to be utilized. This was found very easy in the female by putting a drain into the hollow of the sacrum through an opening in the posterior fornix of the vagina, but in man it was necessary to drain at the lower end of the abdominal incision up through the peritoneal cavity. This was anything but ideal as it completely upset the idealism of the second stage in that the physiological mechanism of the abdomen was broken by having this drain in the peritoneal cavity. But it was soon found that the peritoneum of the narrow pelvis of a man was easily adapted to the formation of a peritoneal encasement with which to surround the drain. Simple rubber tube drainage was soon displaced by a larger protected pack of gauze wicks which served the purpose of



Fig. 12. A large clamp has been passed through a stab wound in the posterior fornix of the vagina and is grasping a roll of gauze wicks which are to be drawn out through the vagina as a quarantine and drain.

separating the physiological from the pathological area and also provided efficient drainage. This third point made the bond which satisfied our idealism. This was described first in *International Clinics*<sup>1</sup>. Up to this time these three principles had been used only in those cases where the growth was located in the ampulla of the rectum proper or lower down and in which the lumen in the growth was sufficiently large to permit the passage of a good sized rectal tube for the purpose of inverting the sigmoid and drawing it down through the growth and through the anus. This procedure was not applicable in a considerable number of cancers located at that very difficult point, the rectosigmoid junction, because of the fact that cancers so located produce early obstruction.

Soon after the publication of this article, another advance step in technique was made so as to include this class of cases, which consists of separating the rectum and perirectal tissues from the sacrum and coccyx in the back and from the bladder and prostate in front. After doubly clamping the intestine well below the growth, the intestine was

<sup>1</sup>Vol. iv, series 31, December, 1921.

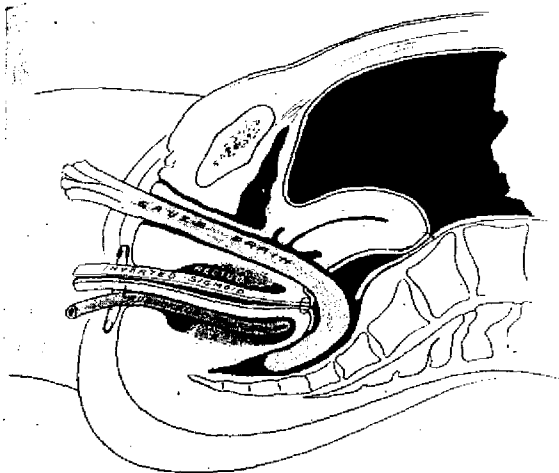


Fig. 13. Sectional view of quarantine drain surrounding inverted end of growth and emerging from the vagina.

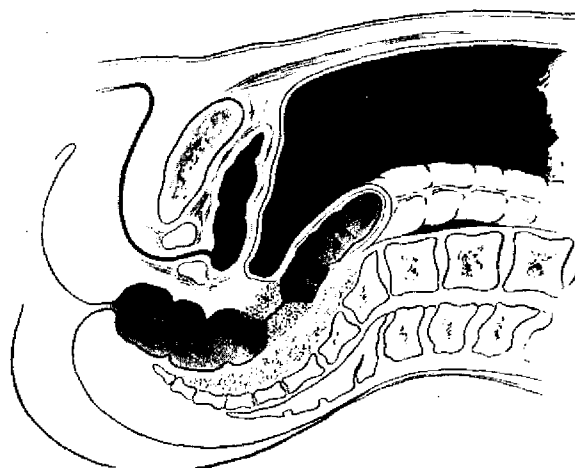


Fig. 14. High rectal cancer producing stricture.

severed between the clamps, leaving the lower clamp on the stub of the rectum and removing the growth with all the intestine and devitalized fatty tissue above. The lower clamp was allowed to remain on the distal end of the rectum and its long handle brought through the peritoneal encasement along with the drain or quarantine pack. This additional technique was presented before the American Medical Association in 1922, and published in *Annals of Surgery*, October, 1922.

Having proved the practicability of this step, it was easy to apply it to the only remaining class to which these principles had not been applied, namely, a low growth the caliber of which was not sufficiently large to permit of the passage of a rectal tube upward for the purpose of invaginating and bringing down the upper end of the sigmoid through the anus. In this class of cases, the steps of the operation are the same as the one just described, except that the part of the gut above the growth is doubly clamped and severed between the clamps, the intestine included in the upper clamp along with all the fat in the hollow of the sacrum is removed at the first operation while the lower clamp is brought out through the drainage tract along with the quarantine pack or a ligature may be tied around the stump of the intestine in place of the clamp. The growth remains until the second operation.

With the successful adaptation of these three fundamental principles to all these classes of cases, they become universal in all cases of operable cancer of the rectum, and this universal adaptability, we feel, justifies us in saying that we are dealing with principles rather than technique. As my experience has grown, I have gradually extended the amount of work done at the primary operation until it has become necessary to make a slight change in nearly all the illustrations dealing with technique.

There are three types or degrees of cancer of the rectum which require variation in technique in carrying out the three fundamental principles set forth. The most frequent cancer encountered in a routine clinic is a cancer located in the ampulla of the rectum which has not yet produced anything like a total obstruction. The second most frequent is cancer of the rectosigmoid in which obstruction is one of the earliest symptoms. The third in frequency is an extensive cancer located in or below the ampulla in which obstruction is marked but in which the growth is still removable. There is also a difference in the application of the third principle in man and in woman for obvious anatomical reasons. The first description of technique will, in order of importance, be that for an unobstructing cancer located in the ampulla of the rectum of a man inasmuch as cancer

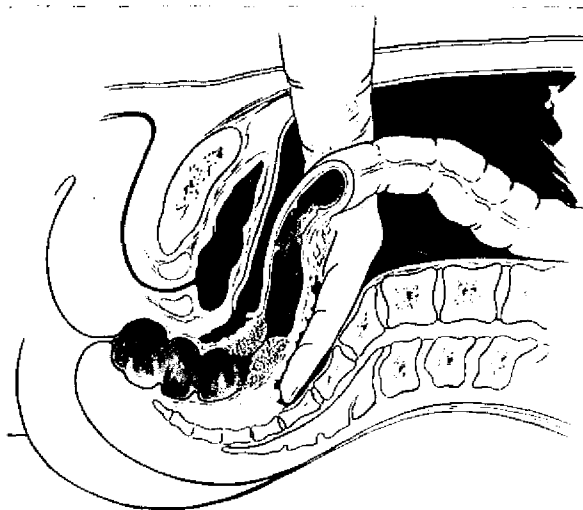


Fig. 15. Sigmoid has been mobilized. Peritoneum around the rectum has been cut, the bladder separated from rectum down to the prostate. Fingers of left hand being insinuated between rectum and sacrum down to point of coccyx.

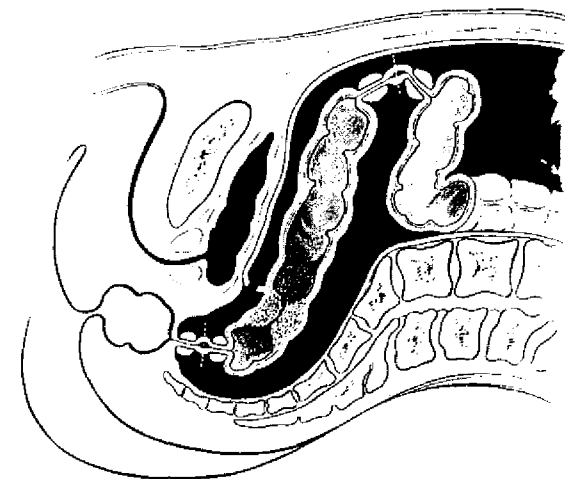


Fig. 16. The freed bowel is doubly clamped above by Payr's clamp and severed. Below, it is doubly clamped by long-handled clamps and severed, after which intestine with growth is removed.

of the rectum is much more frequent in men than in women. This for convenience will be referred to later in the paper as the "standard operation," inasmuch as it includes the three essential principles.

The first step in the technique of the standard operation is common to all cancers of the rectum.

1. Make a long right rectus incision about an inch to the right of the median line extending slightly above the umbilicus. Through this incision, a search is carefully made for metastatic growths in the liver and in the mesentery and retroperitoneal glands. The growth itself is carefully examined through the abdominal incision. If a metastatic growth is discovered in the liver or in the retroperitoneal space, it goes without saying that the plan for the radical removal of the rectum should be abandoned for palliative measures; likewise, if the growth involves the bladder or the firm pelvic wall. This long incision serves the purpose for exploration and for the manipulations of the operation. It is made on the right side because the permanent colostomy is to be made on the left side. It is always best to make a colostomy wound through a separate stab wound. By having the large operating incision on the

right side and the colostomy on the left side, it is possible to protect the large clean wound from the infection of the colostomy.

Having decided to do the radical operation, the intestines are packed well up into the upper abdomen with moist gauze, the exception being the sigmoid which is brought entirely below the wall of gauze. With the left hand, the loop of the sigmoid is lifted high up, the peritoneum of the mesentery is cut down by insinuating the blade of a pair of blunt scissors beneath the peritoneum but external to the vessels. This incision goes down into the pelvis around in front of the rectum, at some distance from it, clipping the rectovesical fold near the bladder. Special angle scissors are made with long handles and a blunt or probe point on the lower blade (Fig. 3). The left forefinger is now inserted through the mesentery where the peritoneum has been cut and with the ends of the forefinger and thumb directed backward toward the promontory of the sacrum, and brought together, the superior hæmorrhoidal artery is felt about three-fourths of an inch in front of the bone. Its pulsation is about as strong as the radial artery. A large ligature, usually a double chromic catgut suture, No. 2 size, is passed beneath the artery with a long curved ligature carrier, the loop of thread is picked

Fig. 16  
brought

up on  
the n  
and t  
the f  
place  
includ  
betwe  
teries  
ceps  
the c  
finge  
betwe  
mese  
edge  
along  
off a  
the f  
is ar  
from  
ford  
pora  
of a  
seco  
ford  
B  
fully  
in t  
peri  
to h  
deta  
left

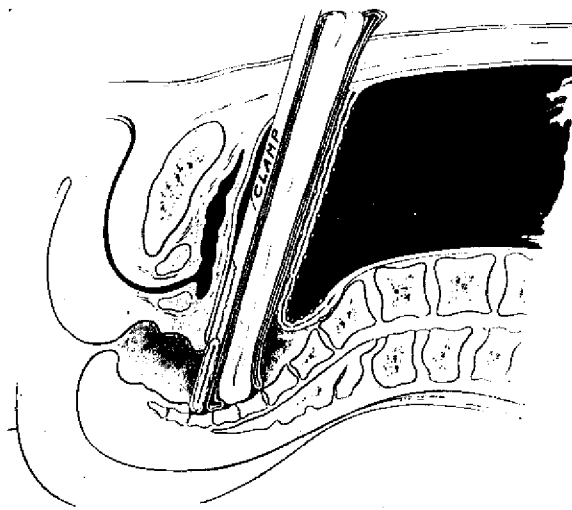


Fig. 17. The handle of clamp holding stub of rectum is brought out through peritoneal tube with cigarette drain.

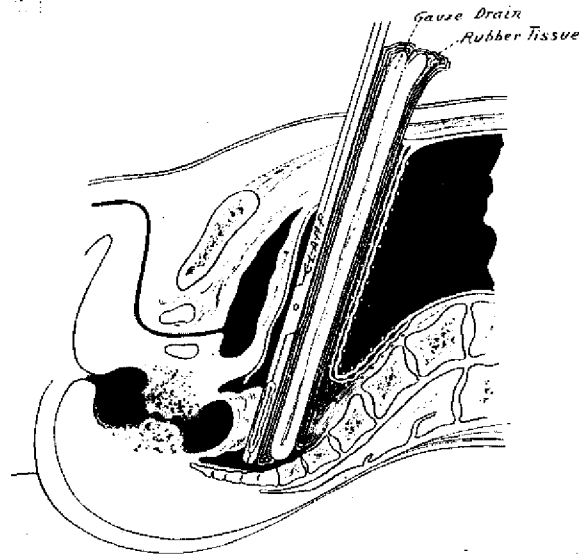


Fig. 18. Obstructing low cancer of the rectum. Devascularization and removal of sigmoid has been performed as in the standard operation. A clamp has been placed on the intestine above growth and brought out with the quarantine drain.

up on the opposite side and brought through the mesentery and around the large vessel and tied very tightly in order to squeeze out the fat in the mesentery. A similar ligature is placed an inch lower down. The mesentery, including the artery and vein, is now severed between the two ligatures. The sigmoid arteries coming from above are grasped in forceps and ligated so as completely to cut off the circulation from this source (Fig. 4). The fingers of the left hand are then insinuated between the ends of the severed superior mesenteric artery and also between the cut edges of the mesentery and pushed downward along the hollow of the sacrum, thus stripping off all the fat and connective tissue down to the tip of the coccyx (Figs. 5 and 6). If there is any return bleeding in the cut mesentery from below, this is stopped by grasping with forceps. After this separation, a large temporary gauze pack is placed in the hollow of the sacrum back of the rectum while the second major step of the operation is performed.

Before beginning this second step, we carefully determine the vitality of the circulation in the upper sigmoid which is to be used for permanent colostomy. It is very important to have a good circulation. This having been determined, an incision about 1.5 inches to the left of the median line and about 2 inches

below the umbilicus, 1.5 or 2 inches in length, is made down through the left rectus muscle. A large Payr clamp is inserted through this incision, passed across within the abdomen to the main incision, where it grasps the proximal sigmoid at a point where it has been determined the circulation is good. Another clamp is placed just below, except that this clamp is in the main wound. The intestine is then severed with the cautery which is made to heat the blades of the clamp and thus sterilize it before it is drawn out through the wound (Fig. 7). It is pulled well up through the wound with the clamps where it is sutured to the layers of the abdominal wall, with fine double chromic catgut placed as a lock stitch, first sewing the peritoneum to the bowel wall, then the aponeurosis and finally a few interrupted sutures hold the skin to the peritoneal surface of the bowel. Usually about an inch of the bowel remains outside the skin.

When this part of the operation is completed, a rectal tube which was introduced into the anus by a nurse at the beginning of the operation, is now pushed up through the sigmoid to the point near the clamp on the distal gut. A purse string of linen is placed

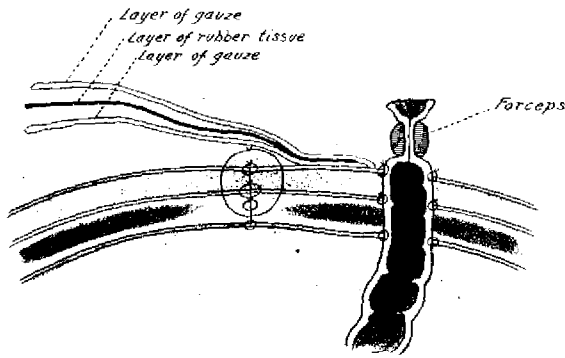


Fig. 19. Cross section of abdominal wall showing the collodion dressing and its relation to the wound and to the colostomy.

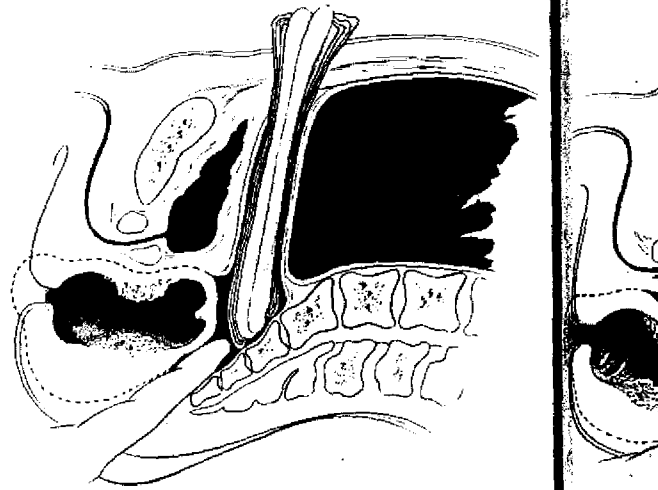


Fig. 20. Coccyx and last joint of sacrum have been removed. Finger inserted into the cavity around the drain.

Fig. 21. F  
adder, pro

around the gut below the clamp, the clamp is removed, the end inverted. The tube is pushed up to the end of the gut, its eye is located, a round needle armed with four double, strong linen thread is passed through the wall of the intestine, through the eye of the rectal tube, out through the end of the intestine, is brought out and tied in a long loop fully an inch in length. The mesenteric fat on this distal gut is now trimmed off well down to the bottom of the pelvis, as much of the large sheet of fat which has been peeled off from the sacrum as possible may be ligated and removed. The artery forceps grasp the intestine on either side (Fig. 8), the nurse pulls on the tube, inverts the end of the gut down to the holding forceps when the forceps are made to grasp further down on the intestine, then the gut is pulled all the way down and out through the anus, where it is held taut in inversion by a clamp placed on it on the outside or by a large safety pin. This loop of thread which attaches the rectal tube to the inverted end of the gut is made long so that the tube precedes the inverted end in going through the narrows of the growth.

The fourth step in technique is to close all raw surfaces and openings so as to reduce to the minimum the danger of adhesions or postoperative obstruction. This is done as follows: First, the abdominal lumen to the left of the emerging sigmoid is closed by a double chromic catgut beginning in the lateral parietal peritoneum over the psoas mus-

cle and with a continuous lock stitch bringing together the peritoneum of the front and back walls of this space over to the emerging sigmoid to which it is sewed. These sutures should be drawn very taut and should leave no possible space for failure to unite. An extra re-enforcement line of suture is often used. From this point, the continuous suture is carried on down, covering in the raw cut edge of the mesenteric fat to the brim of the pelvis (Fig. 9). At this point in the operation a large cigarette drain, which is to serve the purpose of both drainage and a separating quarantine, is placed with its end in the bottom of the pelvis in contact with the hollow of the sacrum or coccyx. The suture is now continued, widening its scope so as to bring in the peritoneum of the lateral walls of the pelvis snugly around the drain. This suture continues forward until the peritoneum is closed around the drain up to the lower end of the long abdominal incision (Fig. 10). Thus all the raw surfaces and openings which would favor postoperative adhesions or postoperative obstruction have been closed, the devitalized tissue has been pushed down to the field of the second operation, and separated by an extraperitoneal quarantine which also takes the place of a drain (Fig. 11). The question of passing a drain up through the rectum through a puncture in the vault of the rectum above the growth into the cavity containing

the devita  
nbe thro  
and the s  
the devita  
tion, but  
favor of t  
After tl  
just been  
important  
advanced  
rectum o  
differs fr  
described  
1. Wh  
quarantin  
vagina, a  
through  
Enough v  
or more i  
forceps a  
leaving e  
sac to tur  
into the  
where it  
also to se  
(As abov  
be applic  
or drain  
the rectu  
An objec  
front an

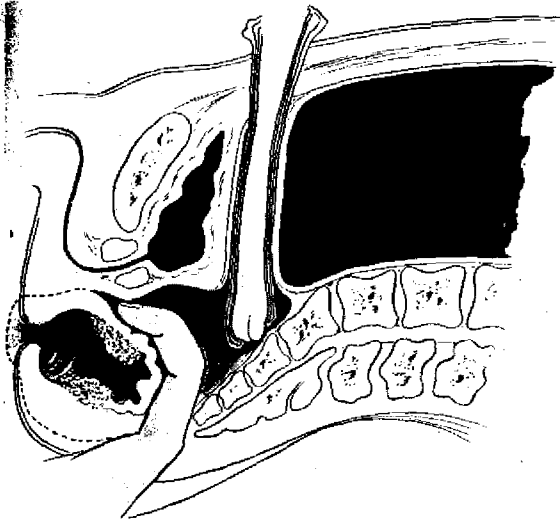


Fig. 21. Fingers flexed on palm, separating rectum from bladder, prostate, and urethra.

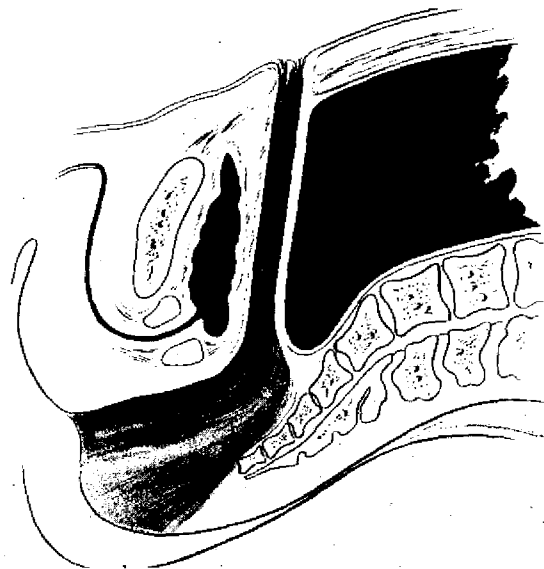

Fig. 22. Space from which rectum has been removed, connected with abdominal drainage canal through which irrigation may be conveniently made.

the devitalized tissues, or inserting a drainage tube through the space between the rectum and the sacrum for the purpose of draining the devitalized area, was the first consideration, but experience caused me to decide in favor of the method described.

After the type of cancer with which we have just been dealing, the next most frequent and important cancer of the rectum is moderately advanced cancer located in the ampulla of the rectum of woman. The operation in woman differs from the standard operation just described in two points:

1. When the time comes to place the quarantine, a long forceps is passed into the vagina, a hole is made in the posterior fornix through the septum into the cul-de-sac. Enough wicks to make a roll of gauze an inch or more in diameter is put in the grasp of the forceps and drawn out through the vagina, leaving enough of the wicks inside the cul-de-sac to turn over the end of the inverted rectum into the hollow of the sacrum and coccyx where it is to form a quarantine, and is also to serve the purpose of a drain (Fig. 12). (As above stated, this same technique may be applied in the male by bringing the pack or drain out through a stab wound back of the rectum and omitting the drain in front. An objection to this would be a cut both in front and back leaving the patient no com-

fortable surface on which to lie while no drawback to the technique has been noticed.)

2. The uterus may be turned backward into the hollow of the sacrum and sewed around to the parietal peritoneum for the purpose of making a good abdominal floor and an intact peritoneal cavity (Fig. 13) or it is very easy to use the pelvic peritoneum back of the uterus.

The next cancer of the rectum of most importance is located in the rectosigmoid segment of the gut, in which obstruction is one of the earliest symptoms and in which it is impossible to pass a tube for the inversion of the end of the distal sigmoid (Fig. 14). In this case, the steps of this operation are the same as have been related in the standard operation except that the bladder and prostate are separated from the rectum in front (Fig. 15), and the rectum is mobilized on the side as well, after which a long clamp grasps the rectum as far below the growth as possible. Another clamp is placed between this clamp and the growth, after which the intestine is cut between the two and the severed sigmoid is removed along with the growth and the devitalized fat which has been lifted when mobilizing the rectum (Fig. 16). The handle of the clamp on the remaining rectum is



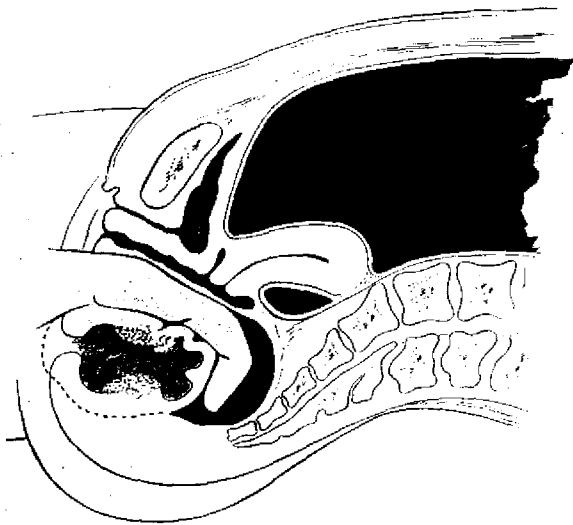


Fig. 23. The vaginal wall has been split. Finger is passing around the end of inverted bowel enucleating the growth without removal of the coccyx.

brought out through the lower end of the abdominal incision, the quarantine drain is placed in the same way and surrounded by the peritoneal encasement (Fig. 17), just as in the standard operation, while in woman the clamp and the drain would be brought out through the vagina.

The third type of cancer of the rectum, which is growing more infrequent as the knowledge of the disease is spread, is one in which the cancer is located in or below the ampulla, does not involve the genito-urinary organs, but has a lumen which is so obstructed as to prevent the introduction of a large rectal tube. In this case, the preliminary steps are the same as in the standard operation described except that the intestine instead of being inverted is grasped and cut between clamps above the growth, the lower clamp next to the growth being brought out with the quarantine or replaced by a ligature (Fig. 18), the upper one being removed with the severed sigmoid and devitalized fat.

Having completed the vital parts of the operation, the large abdominal incision is closed, the Payr clamp on the protruding end of the sigmoid is removed and an Ochsner forceps applied to hold the intestine closed until it is desired to open it. The forceps is fastened to the abdomen by adhesive tape.

For the protection of the main wound from the contents of a colostomy when the gut is opened, I have for a long time used a collodion dressing which is put on as follows. The skin between the wound is thoroughly dried with pure alcohol followed by dry gauze. A layer of gauze, one thickness, about 8 inches by 4 inches, is laid over the main wound with its edge on the skin between the wound and the colostomy wound. This edge is fastened to the skin for about an inch with collodion. A sheet of rubber tissue about the same size is laid over the gauze but not quite reaching the edge. Then another layer of gauze, the size of the first, is laid on top of the rubber tissue and its edge fastened to the edge of the first layer of gauze and the rubber tissue by more collodion. Another layer of rubber tissue is laid on top of this collodion to prevent it sticking to the gauze dressings. A roll of gauze is then laid on top of this between the covered wound and the colostomy (Fig. 19). This dressing thoroughly protects the clean wound from the colostomy so that the wound should heal without breaking down.

The requirements of the three fundamental principles laid down for the first stage of the operation having been completed, the operation is halted until a complete anatomical and physiological abdominal mechanism has been re-established. By this we mean that the sutured peritoneum above the quarantine has firmly healed, the abdominal wound has healed, the artificial anus is firmly established and acting well, the patient's pulse and temperature are practically normal and the patient's digestive apparatus is functioning normally. This is usually completed about the tenth day after the operation. Occasionally, we do the operation a little earlier but sometimes the second operation is delayed several days longer until the patient is in a good healthy condition. In the meantime the enemy, the cancer, has been largely cut off from its support, is quarantined from the rest of the body to a large extent, and is almost harmless for the time being. The most startling and spectacular thing that takes place during this interval between operations, is the line of cleavage between the tissues which have been devitalized and

are to be removed and the normal structures which are to remain. This change makes the second operation a minor affair.

When we are ready for the second operation, we still have in place the quarantine, especially in man for it is allowed to remain as a landmark in doing the second operation. In woman, where the retroverted uterus has been used to form the floor of the cavity, the pack may be removed from the vagina a few days before the second operation in order to get rid of the odor.

The patient, if a man, is placed on an operating table which breaks in the middle. He lies on his face with both head and feet lowered in the jack-knife position. Incision is made in the center of the lower part of the sacrum down to within an inch of the anus, where it divides and surrounds the anus and all the anal muscles; any bleeding skin vessels may be caught with forceps; the coccyx and lower end of the sacrum are exposed; the last joint of the sacrum and coccyx removed with bone forceps; the fingers of one hand are insinuated between the sacrum and the ischio-rectal fat until the cavity containing the quarantine is reached (Fig. 20). Usually there is a good deal of pus and débris in this cavity, which is entirely ignored as harmless. The fingers are then pushed over farther around the end of the inverted rectum and above the growth and the rectum, and all are peeled out with an ease and completeness which is not believable until one has actually had the experience (Fig. 21). The usual time required for the whole operation from the time of the first incision in the skin until the specimen is entirely removed is about 5 minutes without any necessity for hurrying (Fig. 22).

In woman, we usually use the Murphy method and split the vaginal mucous membrane and perineum. If the growth is on the posterior wall of the rectum, the mucous membrane of the vagina is simply lifted and allowed to remain. If the growth is in the front wall of the rectum, the posterior wall of the vagina comes away with the rectum. After this incision in the vaginal wall is made, the fingers of the left hand are passed through the drainage opening, made to curve

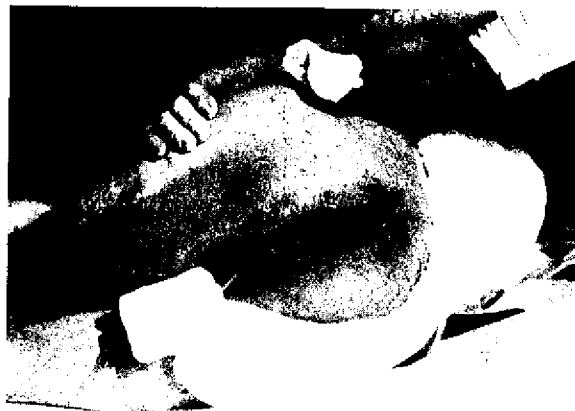

Fig. 25. Photograph showing wound on eighteenth day after operation. Patient allowed to be up.

around the inverted rectum, follow down past the coccyx and peel out the growth with the rectum and the muscles around the anus (Fig. 23), which are cut as far distal to the growth as possible. Without any hurry, this operation has been performed in less than 5 minutes. In no instance is there any bleeding, except that around the anus and anal muscles, which requires the use of artery forceps. I have several times found it unnecessary even to use these. I think I am safe in saying that the total loss of blood for both operations would not average more than 4 ounces and at no time are we in danger of any serious loss of blood. The clean cavity left after removal of the rectum in this way is very surprising. Nature for some reason has, during this interval, made a line of cleavage which is very definite and the fingers, without particular care will follow this line of cleavage. After the rectum is out, the vesiculæ seminales, vas deferens, and bladder are in plain view, practically without bleeding. The cavity along the hollow of the sacrum is almost as smooth as the bone itself.

In case the cancer has been very extensive and has probably penetrated the fascia propria, we use a large dose of radium packed in the gauze. In some cases we have used the radium at the time of the operation and at other times we have used it 4 days later with a second pack of gauze. The radium is applied by using two or three 50 milligram tubes of radium in the ordinary brass containers,

arranged in tandem and sewed to a roll of gauze. In packing the wound, about three-fourths of an inch of gauze is placed between the radium and the prostate and bladder before the gauze containing the radium is put in place. The gauze is then packed lightly on top of the radium which is allowed to remain 24 to 30 hours, depending upon the dose desired. Radium applied to a fresh wound in this way retards the healing at the external opening which we believe is an advantage, for no matter how large the opening on the outside, there is a tendency for it to heal ahead of the upper end of the cavity.

I have been asked: "If this second operation is so simple, why not do it at the first operation?" In answering this question, I may say in the first place that the operation performed without this interval of waiting is by no means so simple, for the lines of cleavage just described are not formed. The definiteness of the line of cleavage around the fascia propria of the rectum and the ease with which the second operation is performed is very amazing to anyone doing the operation for the first time or even observing its performance. The cause of this line of cleavage or œdematous area is probably due to the complete shutting off of the circulation from above which very largely devascularizes the perirectal tissues inside the fascia propria at the first operation. This line of cleavage seems to be comparable to the line of demarcation in gangrene and occurs at the point at which the normal circulation outside the fascia propria encounters the devascularized area at the fascia propria. It does not occur in the absence of devascularization and as far as I know it does not occur in the absence of drainage or the quarantine which of necessity follows devascularization. In the second place, the additional operation would almost double the amount of raw area to be repaired at the first operation and would, therefore, make a much heavier draft on the vital forces of the patient.

Formerly, we partially sewed up the perineal wound. This we have abandoned and now leave the wound entirely open. After the removal of the rectum, this immense cavity is packed with a large five-yard gauze tape which is allowed to remain about 4 days, when it is removed. The quarantine may be removed at the time of the second operation or when the big pack is removed. For purposes of cleanliness, irrigation in the case of man is made through the opening through which the drain was brought out (Fig. 22). The cases in which we have left the wound wide open have done better in the long run than those in which we have attempted to close the wound partially (Fig. 25). The patient may be up in a couple of weeks, the drainage is perfect and time is the only essential yet remaining.

During the past 10 years in an experience of more than one hundred cases of cancer of the rectum treated by all methods, I have operated on 47 patients by the method described with two deaths, the eighth and the thirty-second cases. I am not yet prepared to report on final results but from the unofficial reports I have received, I feel sure that the ultimate reports are going to be as good as I have received from any other cancer involving the abdominal viscera. I am certain that an individual afflicted with cancer of the rectum has many more chances of long life than has one afflicted with cancer of the stomach or with cancer of the uterus. I feel in connection with this subject that no operation can be more thorough than the one we have described and the low mortality so far shown is exceedingly gratifying. In short, cancer of the rectum, instead of being one of the most hopeless of cancers, must now be considered one of the most hopeful, and particularly if the doctors first seeing the case will examine the rectums of patients with the finger as routine when the complaints justify. The diagnosis can nearly always be made early enough to offer a good chance for a permanent cure.