

## EPITHELIOMA OF THE LACRIMAL SAC \*

RALPH A. FENTON, M.D.

PORTLAND, ORE.

True neoplasms of the lacrimal sac are somewhat unusual. Many reported tumors are granulomatous or degenerative products of long standing inflammation, while others arise intrinsically from various elements in the sac wall.

The following cases of true epithelioma are noted in recent literature:

Guibert <sup>1</sup> (in 1905), mentioned a limited epithelioma in which cure was effected by the roentgen ray, and following him Rollet <sup>2</sup> and Lafon <sup>3</sup> reported cases of primary epithelioma of the sac, the latter recurrent. Bistis <sup>4</sup> reported a primary cancer in a man of 60, in which the sac wall became 1 cm. thick. Many of the cases reported have come from Italian clinics, and De Vincentiis, <sup>5</sup> as long ago as 1877, pointed out the danger of confusion in diagnosis with ordinary thickening of the sac wall in a chronic dacryocystitis. Maggi, <sup>6</sup> Pasetti, <sup>7</sup> and Denti <sup>8</sup> have contributed several cases. Hermann <sup>9</sup> reports a hard papilloma of the sac. Juler <sup>10</sup> discovered a similar good sized growth in the upper

\* From the Department of Ophthalmology, University of Oregon Medical School.

\* Read before the Section on Ophthalmology at the Seventy-Sixth Annual Session of the American Medical Association, Atlantic City, N. J., May, 1925.

1. Guibert: Epithélioma du sac lacrimonal, Clin. ophth. **11**: 67, 1905.

2. Rollet: Trois cas de cancer non ulcéré du sac lacrimonal, Bull. et mém. Soc. franç. d'ophth. **23**: 416-29, 1906; Arch. d'ophth. **26**: 337-349, 1906; Le cancer primitif du sac lacrimonal, Lyon méd. **116**: 1005-1007, 1906.

3. Lafon: Epithelioma du sac lacrimonal recidive, J. de méd. de Bordeaux **36**: 172, 1906.

4. Bistis: Primary Cancer of the Lacrimonal Sac, Trans. Eleventh Internat. Med. Congress, April, 1909.

5. De Vincentiis: Tumore del sacco lagrimonale, Mov. med-chir., 1877 (cited by Denti).

6. Maggi: Epitelioma del sacco lagrimonale, Ann. di ottalm. **35**, Nos. 10-11, 1906.

7. Pasetti: Epitelioma del sacco lagrimonale, Ann. di ottalm. **42**: 55-64, 1913.

8. Denti: Papilloma del sacco lacrimonale, Ann. di ottalm. **51**: 830-33, 1923.

9. Hermann: Ein Tumor des Tränensacks, Klin. Monatsbl. f. Augenh. **71**: 728-734, 1923.

10. Juler: Papilloma of Canaliculus, Arch. Ophth. **44**: 564, 1915.

canaliculus. Posey's<sup>11</sup> case was a primary epithelioma of the sac proper.

These cases were primary tumors, many being benign papillomas, filling the lumen of the sac, which can readily be peeled away from the growth. A few cases showed extensive thickening of the wall, with heaping up of many layers of cylindric and cuboidal cells, readily distinguishable from the hyaline distention of the plasmoma reported by Verhoeff and Derby.<sup>12</sup> The verrucous growths showed marked squamous cell increase, with dipping in and karyokinetic exaggeration in those cases bordering on malignancy.

Radical measures involving the sac have long been a necessary part of the cure of rodent ulcer. Of indirect interest with regard to the case that I shall cite is that of Morestin,<sup>13</sup> wherein radiotherapy had failed. Sac extirpation, with transplantation of a forehead flap, brought a good result. Posey<sup>14</sup> also reports an excellent result from a forehead flap after removal of a very large carcinoma, including much of the upper lid.

An element distinctly unusual enters into the case here reported; namely, the invasion of the normal lacrimal sac structures by a slowly growing epithelioma of the nasal skin, under the stimulating influence of roentgen-ray irradiation.

#### REPORT OF CASE

M. R. M., a widow, aged 49, was first treated for an intractable roughening of the nasal skin near the inner canthus of the left eye about sixteen years ago. Various dermatologists employed pastes and later began short and frequent roentgen-ray exposures. Such treatment at intervals during some years seemed to destroy the original site of trouble, but the lesion advanced across the bridge of the nose, leaving an unwholesome papyraceous skin behind. This closely resembled that seen after roentgen-ray burns elsewhere. There was no evidence of syphilis or tuberculosis. Repeated short exposures to an unscreened radium applicator were made four years ago, after which the first lacrimal swelling was noted.

Three and one-half years ago the patient became alarmed regarding a hard swelling at the inner canthus of the right

11. Posey: Case of Primary Epithelioma of the Lacrimal Sac, *Tr. Am. Ophth. Soc.* **19**: 205-208, 1921.

12. Verhoeff and Derby: Plasmoma of the Lacrimal Sac, *Arch. Ophth.* **44**: 252-264, 1915.

13. Morestin: *Rec. d'ophth.*, June, 1908.

14. Posey: *Ophth. Rec.*, May, 1908.

eye, and consulted Dr. T. W. Ross. Surface plaques of radium (10 mg. with 1.23 mm. brass screen) were effective in stopping pain and clearing redness and roughness of the skin; but the swelling increased about the sac.

My examination, at the request of Dr. Ross; Jan. 17, 1922, disclosed a smooth, hard, slightly tender swelling, including both the canaliculi and the lacrimal sac. The neighboring conjunctiva was reddened; epiphora was constant. The puncta were normal in size, but no lumen was permeable to delicate probing. Force was not used. External rotation of the globe was somewhat painful.

Radical excision of the growth with as much neighboring skin and periosteum as possible was made, January 20 (Fig. 1). Under gas-ether anesthesia, the inner third of both lids, the skin and periosteum of the lateral aspect of the nose, the lacrimal sac as far down the nasal duct as possible, both canaliculi and the caruncle were removed. The




Fig. 1.—Black, extent of tumor; outer shaded area, limit of incision.

resulting circular defect left one-third the cornea bare, and measured 3.5 cm. in diameter. Three 10 mg. radium needles, in a narrow, hard rubber uterine applicator, were stood upright in the nasal duct, remaining seven hours, 210 milligram-hours in all. Slight tingling for forty-eight hours was the only reaction, and the eye remained clean, under instillation of mercurochrome-220 soluble, 2 per cent., for two weeks. Normal drainage through the nasal duct occurred within a week after the operation, and it has never been occluded since.

Dr. R. L. Benson, head of the department of pathology, examined the tissue removed, which showed obliteration of the lumen of the sac and canaliculi. Microscopically, there was an irregular mass of stratified, squamous epithelium showing evidences of rapid growth. The malignant infiltration extended from the tissue about the eye along the wall of the tear sac. The pathologic diagnosis was squamous cell carcinoma, highly malignant (Figs. 2 and 3).

Six weeks after excision, the first plastic operation was done (Fig. 4) under procain. A canthoplasty 15 mm. long was lined by loosened conjunctiva, and a crescentic incision

over the malar bone was puckered into a Y, to give fulness, permitting the lengthened lid stumps to move over toward the nose. The nasal ends of the lids were temporarily sutured together, and anchored by mattress traction sutures to the nasal bridge and forehead.

Three months after excision, the opening had been reduced to 15 mm., and a second plastic graft was made under procain (Fig. 5). A rectangular flap, 25 by 35 mm., based at the glabella, was switched from above the unshaven right eyebrow to fill the defect. The distal 5 mm. of this flap was folded



Fig. 2.—Normal sac epithelium at top of section; at left and below, invasion by dipping down of cancerous masses.

under to form a new lid margin. The eyebrow was lifted into the forehead defect. All stitches held except one at the restored inner canthus, which cut out from the softened skin previously damaged by radiation. The cosmetic result was reasonably good (Fig. 6), in view of the extensive sacrifice of tissue. The eye whitened out, and the new upper lid opened and closed accurately. Scarring about the region of the internal rectus interfered somewhat with extreme abduction.

However, ten months after the excision, the patient became aware of an enlargement and hardening of the skin flap; the eye again became red and painful. She was not able to leave her home in a remote district to come in for further radium treatment as advised until twenty months after the original excision and seventeen months after the flap plastic operation (Sept. 26, 1924). A smooth, hard mass 1.5 cm. in diameter bulged up the flap, fixing it firmly to the lacrimal bone and inhibiting abduction beyond 10 degrees. The conjunctiva was slightly reddened; but the nasal duct remained



Fig. 3.—Irregular masses of cells composing the body of the tumor.

wide open, and there was no sign of recurrence, ulceration or glandular swelling elsewhere.

No further surgical work was considered, and one powerful application of radium was made (220 milligram-hours); she returned three and again four months later, when a total of 840 milligram-hours was administered. The eye has again whitened, and the growth, though still hard, is smaller by one third. Abduction is still limited and painful. At present (February, 1925), three years after excision, the recurrence remains stationary.

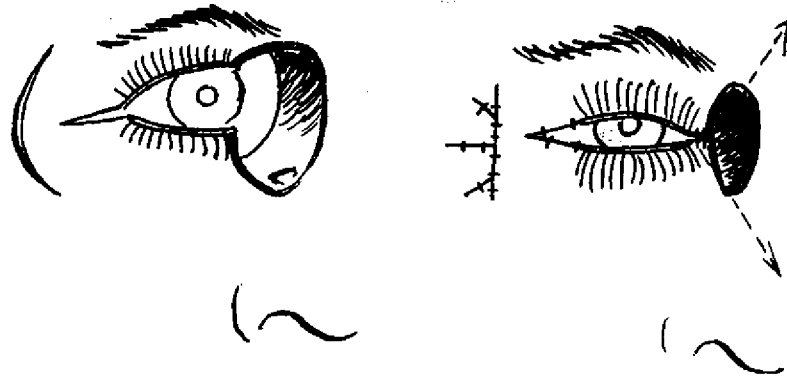


Fig. 4.—Plastic operation for moving lids toward nose, reducing defect.




Fig. 5.—Plastic repair of upper lid defect with forehead flap.

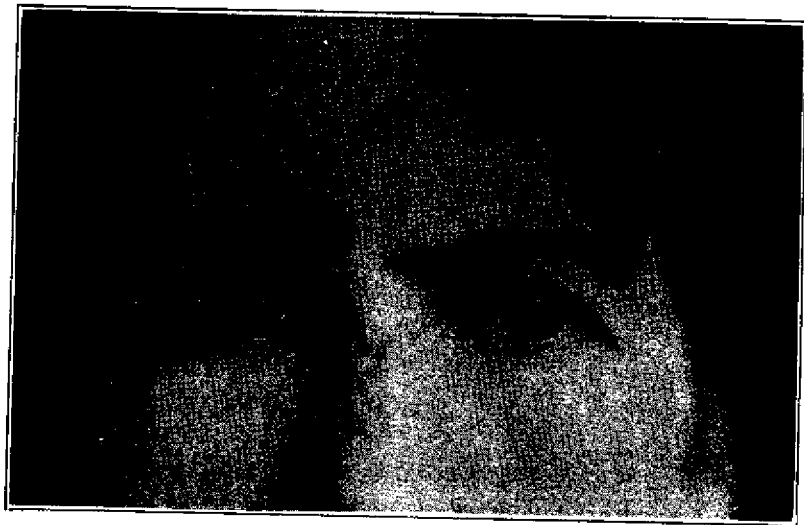


Fig. 6.—Results of plastic operation, three months after second operation.

## CONCLUSIONS

Epithelioma of the skin about the eye may be metamorphosed by stimulant doses of roentgen rays or radium into a type that will invade conjunctival and mucosal structures.

Irradiated papyraceous skin may give rise to epitheliomatous invasion of healthy skin flaps about the eye, at a point of suture or of contact with the moving globe. Such attack is probably activated by irritation of granulation tissue by lacrimal secretion and by the bacterial flora of the skin and conjunctiva.

Radium and the roentgen ray must be used in sufficient strength to produce endarteritis and starvation changes, if employed at all on ocular neoplasms. It is regrettable that no opportunity was afforded for follow-up use of radium in this case.

Caution should be exercised in the selection of a physician for roentgenologic or radiologic treatment about the eye. Commercial exploitation of the sale of apparatus and of radium has brought about the installation of these powerful agents in the hands of physicians untrained in their use; or even into the control of lay technicians, or of so-called beauty specialists. The caution of such guesswork operators, in attempting radiotherapy, is often, as in this case, productive of stimulative changes rather than of destruction. Dermatology and ophthalmology must join hands in deciding methods of screening, distance, intensity and time limits for this valuable, yet highly dangerous, agent.

*Reprinted from The Journal of the American Medical Association  
Oct. 10, 1925, Vol. 85, pp. 1128 and 1129*

*Copyright, 1925*

*American Medical Association, 535 N. Dearborn St., Chicago*